

9-1-2008

Myositis ossificans circumscripta of the buccinator muscle: first report of a rare complication of mandibular third molar extraction

Raymond L Wiggins

David Thurber

Kenneth Abramovitch

Jerry Bouquot

Nadarajah Vigneswaran

Follow this and additional works at: https://digitalcommons.library.tmc.edu/uthdb_docs



Part of the [Dentistry Commons](#)

Recommended Citation

Wiggins, Raymond L; Thurber, David; Abramovitch, Kenneth; Bouquot, Jerry; and Vigneswaran, Nadarajah, "Myositis ossificans circumscripta of the buccinator muscle: first report of a rare complication of mandibular third molar extraction" (2008). *Journal Articles*. 27.

https://digitalcommons.library.tmc.edu/uthdb_docs/27

This Article is brought to you for free and open access by the School of Dentistry at DigitalCommons@TMC. It has been accepted for inclusion in Journal Articles by an authorized administrator of DigitalCommons@TMC. For more information, please contact digcommons@library.tmc.edu.



Published in final edited form as:

J Oral Maxillofac Surg. 2008 September ; 66(9): 1959–1963. doi:10.1016/j.joms.2008.01.066.

Myositis ossificans circumscripta of the buccinator muscle: First report of a rare complication of mandibular third molar extraction

Raymond L. Wiggins, D.D.S., M.D.^{*}, David Thurber, B.S.[♣], Kenneth Abramovitch, D.D.S., MS.[□], Jerry Bouquot, D.D.S., M.S.[♦], and Nadarajah Vigneswaran, B.D.S., D.M.D., Dr.Med.Dent.[♥]

^{*}*Oral and Maxillofacial Surgeon, In Private Practice in Katy, Texas*

[♣]*Senior Dental Student, The University of Texas Dental Branch at Houston, Texas*

[□]*Associate Professor of Oral and Maxillofacial Radiology, Department of Diagnostic Sciences, The University of Texas Dental Branch at Houston, Texas.*

[♦]*Professor and Chairman, Oral and Maxillofacial Pathology, Department of Diagnostic Sciences, The University of Texas Dental Branch at Houston, Texas*

[♥]*Professor of Oral and Maxillofacial Pathology, Department of Diagnostic Sciences, The University of Texas Dental Branch at Houston, Texas*

Abstract

Myositis ossificans is a self-limiting ossifying process that most often develops following mechanical trauma to skeletal musculature. It chiefly affects the skeletal muscles of extremities of young athletically active adult males. Myositis ossificans is rare in children except for children affected by heritable disorder known as progressive myositis ossificans (fibrodysplasia ossificans progressiva). Children with this disorder develop ossification of muscles and associated soft tissue in early childhood without prior history of trauma. Traumatic form of myositis ossificans also known as myositis ossificans circumscripta (MOC) is rarely encountered in the head and neck musculature. We report a case of MOC within the buccinator which developed as a postoperative complication of mandibular third molar surgery. During extraction of a left mandibular third molar in a 16-year old male, a tooth fragment was accidentally displaced into the adjacent soft tissue. Retrieval of this tooth fragment caused significant soft tissue trauma. Eighteen months after his third molar surgery, the patient continued to have pain and tenderness anterior to the left mandibular ramus. Radiographic imaging revealed a well-defined ovoid radiopaque mass within the left buccinator muscle. The lesion was surgically removed and the post-surgical course of the patient was uneventful. Histological findings of the mass were characteristic for myositis ossificans.

Keywords

Myositis ossificans; Buccinator muscle; Third molar surgery; Postoperative complications

Correspondence Address: Dr. Nadarajah Vigneswaran, Department of Diagnostic Sciences, The University of Texas, 6516, M.D. Anderson Blvd. DB 3.094G, Houston, Texas 77030, USA.; email: nadarajah.vigneswaran@uth.tmc.edu; Tel: 713-500 4410; Fax: 713-500-4416.

Publisher's Disclaimer: This is a PDF file of an unedited manuscript that has been accepted for publication. As a service to our customers we are providing this early version of the manuscript. The manuscript will undergo copyediting, typesetting, and review of the resulting proof before it is published in its final citable form. Please note that during the production process errors may be discovered which could affect the content, and all legal disclaimers that apply to the journal pertain.

Introduction

Myositis ossificans (MO) is a non-neoplastic reactive hyperplasia characterized by prominent heterotopic ossification within the skeletal muscle and deep soft tissues of the extremities and trunk [1]. There are various clinical subtypes of myositis ossificans with distinct clinical features and biologic behavior. Progressive myositis ossificans, also known as fibrodysplasia ossificans progressiva, is a rare autosomal dominant disorder characterized by congenital malformation of the great toes and progressive, disabling heterotopic ossification of the upper extremities and back [2]. Onset of this disorder is in early childhood and the ectopic ossification occurs within the muscle fascia, ligaments, tendons and joint capsules [2]. Neurogenic myositis ossificans is a disabling condition affecting patients immobilized by a spinal cord injury [3]. In neurogenic MO, heterotopic ossification occurs below the levels of the spinal cord injury, predominantly around the hip and knee joints [3]. Myositis ossificans circumscripta (MOC) is defined as new bone growth that develops after a blunt injury to a muscle; the ossification occurs within the skeletal muscle fibers [4,5].

MOC is more common in males and is typically seen in the arms and thighs of young athletes who participate in contact sports [1,4,5]. MOC typically develops after a blunt injury to large skeletal muscles and presents as a palpable tumor-like calcified mass within the injured muscle [1,4,5]. It frequently causes pain, tenderness, and loss of range of motion at the adjacent joint [1,4,5]. More than 80% of lesions arise in the large muscles of the extremities; they rarely occur within the head and neck region. Here, we report a case of MOC involving the buccinator muscle as a postoperative complication of third molar extraction.

Report of a Case

A 17-year-old white male presented with a chief complaint of pain and muscle tenderness close to the left angle of his mandible. He complained of constant dull aching near the anterior border of his left mandibular ramus. This pain was exacerbated by chewing and began after left mandibular third molar extraction approximately 18 months earlier; the pain has progressively worsened. During the extraction, a fragment of the extracted tooth was accidentally displaced into adjacent soft tissue. Additional soft tissue surgery was required to recover this tooth fragment. The patient had no other neurologic or systemic complaints and his medical history was unremarkable. He was not taking any medications and denied use of tobacco or alcohol.

Physical examination demonstrated a hard moveable mass measuring 8 × 10 mm within the buccinator muscle just superior to the external oblique ridge and just anterior to the anterior border of the ramus. The affected area of the muscle exhibited moderate pain on palpation. There was a decreased range of mandibular movement but no pain was elicited on palpation of the temporomandibular joints. His vital signs were stable and the rest of his systemic physical examination findings were within normal limits.

A panoramic radiograph revealed an ovoid calcified mass with a central area of lucency (Figure 1). The mineralized density of this mass was similar to bone and the mass was localized within the soft tissue, just anterior to the anterior border of the left mandibular ramus. It was not connected to the ramus (Figure 1). Cone beam computer tomography (i-CAT[®], Imaging Sciences International, Philadelphia) in axial sections demonstrated a well-circumscribed ovoid bony mass within the left buccinator muscle, clearly separated from the adjacent mandibular ramus (Figure 2). The bony mass demonstrated a zonal pattern characterized by a central non-calcified region of low attenuation surrounded by a peripheral ring of high-density consistent with mature bone. A 15 mm incision was placed lateral and superior to the lesion and the bony mass was enucleated. It was not contiguous with the mandible. The patient's postoperative recovery was uneventful. He did not experience any neural deficits or muscle weakness, and he regained a full range of jaw movement after the surgery.

Gross examination of the surgical specimen revealed an ovoid reddish-pink stony hard mass $6 \times 7 \times 8$ mm in size (Figure 3). During sectioning, this mass cut with a gritty sensation and exhibited a hemorrhagic soft area in the center. Microscopically, the bony mass had a distinct zonal pattern reflecting different degrees of bone formation and maturation (Figure 4). The innermost portion of the mass was composed of immature and actively proliferating spindle and ovoid cells in a highly vascular stroma (Figure 5). The intermediate zone of the mass consisted of ill-defined trabeculae of woven bone, rimmed by osteoblasts and varying amounts of osteoid separated by thin-walled vascular channels (Figure 6). At the peripheral margin, the osteoid trabeculae evolved into mature lamellar bone (Figure 6). The histopathologic diagnosis of MOC was made based on this unique centripetal pattern of ossification.

Discussion

Myositis ossificans (MO) is a group of rare disorders with distinctive clinical, radiologic and histologic features. It is a potentially disabling entity, characterized by extraosseous non-neoplastic bone formation within skeletal muscle or soft tissue. Although MO is a widely used clinical term, it is somewhat misleading because MO is not associated with muscle inflammation and does not exclusively occur within skeletal muscle [4]. Hence, some clinicians prefer to call these lesions heterotrophic ossification instead of MO [6]. MO encompasses three distinct clinical entities: fibrodysplasia ossificans progressiva, neurogenic myositis ossificans and myositis ossificans circumscripta (MOC).

Fibrodysplasia ossificans progressiva (FOP) is an extremely rare autosomal dominant disorder with a prevalence of approximately 1 in 2 million people [7,8]. Patients with FOP present with short, monophalangeal great toes and broad femoral necks [2,7,8]. They develop progressive, disabling ossification of fascia, tendons, ligaments, joint capsules and connective tissue between the skeletal muscle planes [2,7,8]. Ectopic endochondral ossification in FOP may occur after trauma or spontaneously in a specific anatomical pattern leading to the formation of a “second skeleton” [2]. This ectopic bone is chemically and histologically identical to normal bone.

Ectopic ossification in FOP tends to demonstrate predilection for the paraspinal and scalp muscles, the jaw muscles and the proximal muscles of the extremities [7,9,10]. Notably, FOP does not affect the facial expression muscles, the tongue, the diaphragm and the visceral smooth muscles; the reasons for this are currently unknown [7]. Involvement of the temporomandibular joint in FOP patients often leads to restricted jaw movements [9,10].

Dysregulated overexpression of bone morphogenic protein 4 (BMP-4) is implicated in the pathophysiology of FOP [11]. Recently, Shore et al. discovered that FOP is caused by a mutation of the activin A type I receptor gene (ACVR1; BMP-type 1 receptor) leading to its constitutive activation. Constitutive activation of ACVR1 in FOP patients causes dysregulated overexpression of BMP-4, leading to ectopic osteogenesis and joint fusions [12,13]. FOP affects children at a very young age, whereas the other two forms of MO rarely occur in children [7,8].

Neurogenic MO affects the extremities and large joints of patients immobilized by traumatic neurologic impairment (i.e. brain trauma, spinal cord injury), severe burn injury or total hip joint arthroplasty [3,14]. Ectopic ossification in neurogenic MO does not occur within the skeletal muscle but within the connective tissue between the muscles and around the joints [3,14]. The most common sites of neurogenic MO are the hips, knees and shoulders [3,14].

Myositis ossificans circumscripta (MOC) is a reactive, self-limiting disorder characterized by prominent heterotopic ossification within skeletal muscles [15,16]. MOC typically develops in response to a single episode of severe contusion injury as was seen in the present case, or

repeated minor trauma to skeletal muscle. MOC is more common in males and generally occurs in patients between the ages of 20 and 30 years [1]. It is frequently seen in athletes who sustain injury while playing contact sports. MOC most frequently occurs in the flexor muscles of the upper arm, the quadriceps femoris and the abductor muscles of the thigh [1]. Occurrence within the head and neck musculature is decidedly uncommon but the lesion has been reported in the paraspinal, masseter and temporalis muscles [17–20]. Our case is the first to report the appearance of MOC within the buccinator as an unusual postoperative complication of mandibular third molar surgery.

The pathogenesis of MOC remains uncertain. One theory suggests that trauma to the muscle initiates fibroblastic proliferations which subsequently undergo osseous metaplasia. Since MOC tends to occur close to a bone, it has been postulated that trauma-induced implantation of periosteal osteoblasts within the skeletal muscle is the source for intramuscular ossification. However, the most widely accepted theory is that trauma to skeletal muscles induces the expression of bone morphogenetic protein at the site of injury which in turn stimulates the primitive stem cells to differentiate into osteoblasts, resulting in heterotopic ossification.

MOC has distinctive clinical, radiographic and histologic features and can be readily diagnosed in its most typical form in the large muscles of the extremities [1,4,21]. It typically presents with pain, tenderness and limited movement of the affected muscle, with a soft swelling of the skeletal muscle following injury. Subsequently, the swelling subsides and a hard and tender mass develops within 1–2 months. The radiographic appearance over time generally reflects maturation sequence of MOC from the time of trauma [1,4,21]. The lesion initially presents as an ill-defined mass with faint, flocculent and irregular opacities. Typically, calcifications in MOC appear 2–3 weeks after the trauma and a well-developed MOC with a characteristic zonal calcification pattern becomes evident only after 4 to 6 weeks [1,4,21]. Hence, a three-phase bone scan or ultrasonography is necessary to detect MOC at the earliest stages of formation [22,23].

In plain radiographs, the mature MOC appears as a well-demarcated, calcified mass with accentuated calcification at the periphery and a central nidus of lucency [1,4]. Computer tomographic and magnetic resonance imaging are useful to depict the zonal architecture and mineralization patterns, which are diagnostic for MOC [21]. The present case demonstrates the adequacy of cone beam computer tomography to accurately demonstrate the radiographic patterns of mineralization in MOC.

MOC occurring in close proximity of bone (parosteal myositis ossificans) can incite a characteristic “onion-skin” pattern of multilayered periosteal new bone formation (proliferative periosteitis) [1]. The presence of a radiolucent cleft which separates the lesion from the periosteum, as noted in the current case, helps to distinguish MOC from juxtacortical osteoid osteomas or osteoblastomas which are usually attached to the bony surface [1].

The gross and microscopic appearances of MOC often reflect the zonal architecture documented in the radiographic presentations: a central area of hemorrhagic, highly cellular center with fibrovascular stroma, a peripheral shell of more mature lamellar bone [1]. At the early stage, MOC is histologically characterized by fibroblastic proliferation with irregular areas of osteoid production. With maturation, MOC organizes to reveal a characteristic zoning arrangement of central cellular growth surrounded by a layer of osteoid with immature woven bone and a periphery of more mature lamellar bone. The diagnosis of MOC can be problematic if there is no previous history of trauma or when it occurs in rare locations as in the current case. The clinical differential diagnosis of MOC includes nodular fasciitis, juxta cortical (periosteal) osteoid osteoma, osteoblastoma and extraskeletal osteosarcoma.

The microscopic MOC features of abundant osteoid, immature, irregularly mineralized bone trabeculae with plump osteoblastic rimming and scattered giant cell osteoclasts in a vascular stroma, can also be seen in benign bone-forming tumors such as osteoid osteomas and osteoblastomas [1]. However, these benign bone-forming tumors will exhibit a “a reverse zoning phenomenon” (i.e. mature bone formation in the center and older portion of the tumor and immature osteoid with spindle cell proliferation at its margin) [1]. MOC can be misinterpreted as a malignancy if a biopsy is obtained at the early stage of development, especially if the biopsy is taken from the center of the lesion, with its plump, mitotically active osteoblasts associated with haphazardly arranged osteoid. In MOC, the zonal architecture and sequential maturation pattern are critical diagnostic features to distinguish this lesion from malignant bone-forming tumors [1].

Since MOC is a benign pseudosarcomatous lesion with a limited growth potential, conservative surgical excision and avoidance of repeated trauma to the muscle is curative [1]. Excision of the MOC is best performed during the mature phase of the lesion, when it is well delineated from the surrounding soft tissue and skeletal muscle [1]. Surgical treatment MOC at its early phase of development may lead to incomplete excision and recurrence [1].

In summary, we present the first example of myositis ossificans circumscripta involving the buccinator muscle, arising in response to third molar extraction trauma. The accidental displacement of a mandibular third molar or its root fragment into the adjacent soft tissue is a rare and serious complication. Surgical retrieval of the displaced tooth fragment may cause trauma to the adjacent musculature and may lead to the development of MOC. Clinicians should be aware of this potential complication and try to minimize muscle trauma during surgical retrieval of the displaced tooth.

References

1. Dorfman, HD.; Czerniak, B. Reactive and metabolic conditions simulating neoplasms of bone. In: Dorfman, HD.; Czerniak, B., editors. *Bone Tumors*. St Louis: Mosby; 1998. p. 1120
2. Smith R, Athanasou NA, Vipond SE. Fibrodysplasia (myositis) ossificans progressiva: clinicopathological features and natural history. *QJM* 1996;89:445. [PubMed: 8758048]
3. Carlier RY, Safa DM, Parva P, et al. Ankylosing neurogenic myositis ossificans of the hip. An enhanced volumetric CT study. *J Bone Joint Surg Br* 2005;87:301. [PubMed: 15773634]
4. Nuovo MA, Norman A, Chumas J, Ackerman LV. Myositis ossificans with atypical clinical, radiographic, or pathologic findings: a review of 23 cases. *Skeletal Radiol* 1992;21:87. [PubMed: 1566115]
5. Todd W, Gianfortune PJ, Laughner T. Post-traumatic myositis ossificans circumscripta: an unusually large example. *J Am Podiatr Med Assoc* 2007;97:229. [PubMed: 17507534]
6. Fuselier CO, Tlapek TA, Sowell RD. Heterotrophic ossification (myositis ossificans) in the foot. A case report. *J Am Podiatr Med Assoc* 1986;76:524. [PubMed: 3761189]
7. Connor JM. Fibrodysplasia ossificans progressiva -- lessons from rare maladies. *N Engl J Med* 1996;335:591. [PubMed: 8678940]
8. Mahboubi S, Glaser DL, Shore EM, Kaplan FS. Fibrodysplasia ossificans progressiva. *Pediatr Radiol* 2001;31:307. [PubMed: 11379597]
9. Sendur OF, Gurer G. Severe limitation in jaw movement in a patient with fibrodysplasia ossificans progressiva: a case report. *Oral Surg Oral Med Oral Pathol Oral Radiol Endod* 2006;102:312. [PubMed: 16920539]
10. van der Meij EH, Becking AG, van der Waal I. Fibrodysplasia ossificans progressiva. An unusual cause of restricted mandibular movement. *Oral Dis* 2006;12:204. [PubMed: 16476045]
11. Kaplan FS, Fiori J, LS DLP, et al. Dysregulation of the BMP-4 signaling pathway in fibrodysplasia ossificans progressiva. *Ann N Y Acad Sci* 2006;1068:54. [PubMed: 16831905]

12. Couzin J. Biomedical research. Bone disease gene finally found. *Science* 2006;312:514. [PubMed: 16645061]
13. Shore EM, Xu M, Feldman GJ, et al. A recurrent mutation in the BMP type I receptor ACVR1 causes inherited and sporadic fibrodysplasia ossificans progressiva. *Nat Genet* 2006;38:525. [PubMed: 16642017]
14. Gunduz B, Erhan B, Demir Y. Subcutaneous injections as a risk factor of myositis ossificans traumatica in spinal cord injury. *Int J Rehabil Res* 2007;30:87. [PubMed: 17293727]
15. Allard MM, Thomas RL, Nicholas RW Jr. Myositis ossificans: an unusual presentation in the foot. *Foot Ankle Int* 1997;18:39. [PubMed: 9013113]
16. Herring KM, Levine BD. Myositis ossificans of traumatic origin in the foot. *J Foot Surg* 1992;31:30. [PubMed: 1349316]
17. Mann SS, Som PM, Gumprecht JP. The difficulties of diagnosing myositis ossificans circumscripta in the paraspinal muscles of a human immunodeficiency virus-positive man: magnetic resonance imaging and temporal computed tomographic findings. *Arch Otolaryngol Head Neck Surg* 2000;126:785. [PubMed: 10864118]
18. Mevio E, Rizzi L, Bernasconi G. Myositis ossificans traumatica of the temporal muscle: a case report. *Auris Nasus Larynx* 2001;28:345. [PubMed: 11694380]
19. Myoken Y, Sugata T, Tanaka S. Traumatic myositis ossificans of the temporal and masseter muscle. *Br J Oral Maxillofac Surg* 1998;36:76. [PubMed: 9578265]
20. Uematsu Y, Nishibayashi H, Fujita K, et al. Myositis ossificans of the temporal muscle as a primary scalp tumor. Case report. *Neurol Med Chir (Tokyo)* 2005;45:56.
21. Amendola MA, Glazer GM, Agha FP, et al. Myositis ossificans circumscripta: computed tomographic diagnosis. *Radiology* 1983;149:775. [PubMed: 6647854]
22. Drane WE. Myositis ossificans and the three-phase bone scan. *American Journal of Roentgenology* 1984;142:179. [PubMed: 6606955]
23. Okayama A, Futani H, Kyo F, et al. Usefulness of ultrasonography for early recurrent myositis ossificans. *J Orthop Sci* 2003;8:239. [PubMed: 12665965]

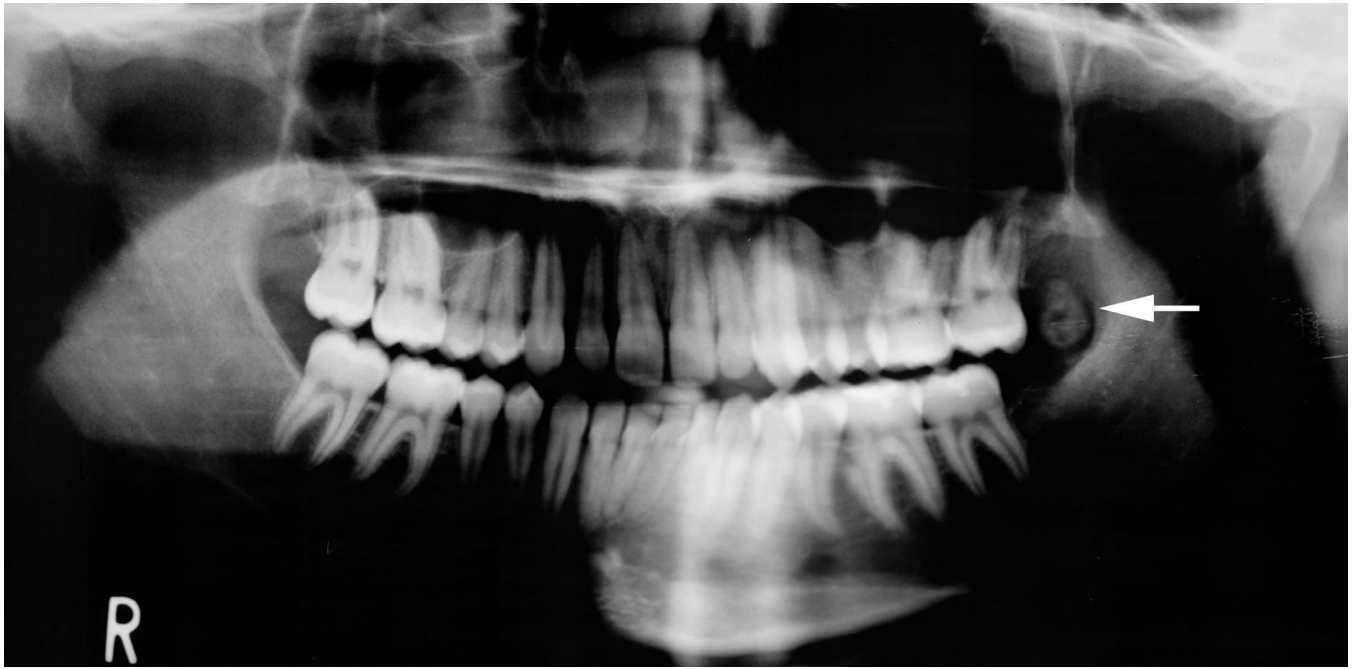

Figure 1. Panoramic radiograph taken at the time of initial presentation demonstrates a well defined ovoid calcified mass (arrow) just anterior to the anterior border of the left mandibular ramus. The mass reveals prominent peripheral maturation with a central area of radiolucency. Note that a radiolucent cleft separates this parosteal mass from the cortical margin of the anterior mandibular ramus.

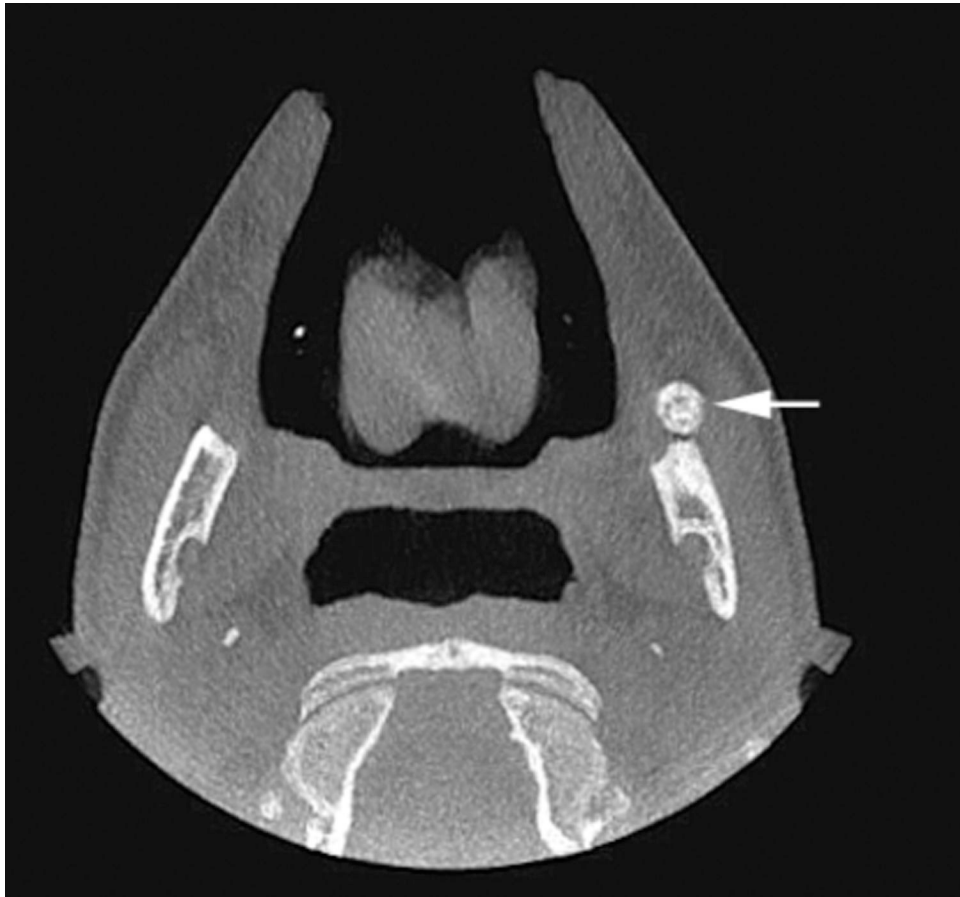

Figure 2. The axial view of the cone beam computer tomographic scan demonstrates a well defined radioopaque mass within the buccinator muscle anterior to the left mandibular ramus. This mass reveals zonation organization characterized by peripheral ossification and a focal central lucency.

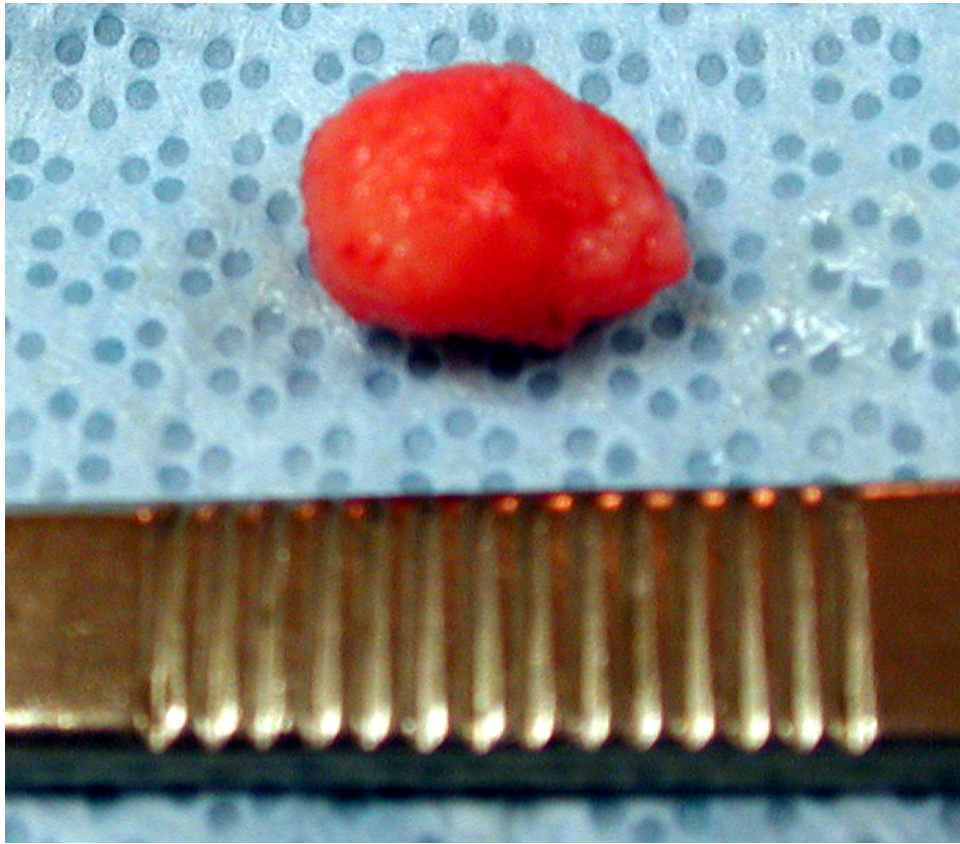


Figure 3. Gross photograph of the intramuscular calcified mass which easily shelled out from the muscle during surgery.

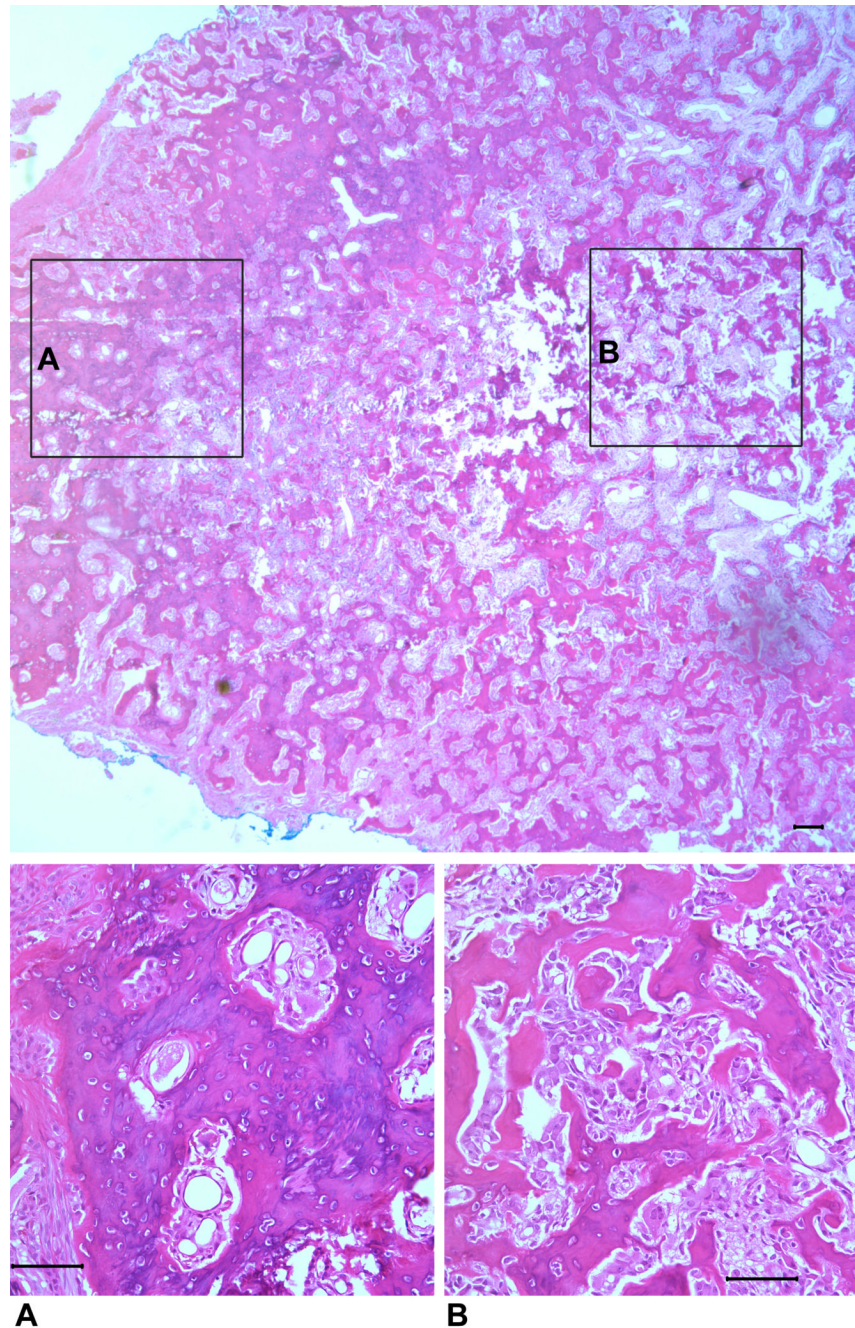


Figure 4. Top: Low-powered photomicrograph of the entire lesion demonstrates zonal maturation of bone peripherally and a central area of immature bone. Bottom: High magnification views of the lesion demonstrate mature well-developed shell of lamellar bone at its periphery (A) and a central area (B) consisting of proliferating plump spindle cells and scattered multinucleated giant cells associated with irregular trabeculae of woven bone. (Hematoxylin and eosin stain; Top: original magnification ($\times 40$; Bar = $200\ \mu\text{M}$); Bottom: original magnification ($\times 200$; Bar = $100\ \mu\text{M}$))