

Part II
ANGIOGRAPHIC ATLAS
OF CORONARY ANOMALIES

CASE REPORT 4.1**Absent Left Main Trunk**

A 68-year-old woman with a previous history of coronary artery disease and mitral regurgitation was admitted with progressive angina. Cardiac catheterization revealed occlusion of the non-dominant RCA, diffuse disease of the LAD (Fig. CR4.1A), and a critically stenotic lesion of the proximal circumflex artery (Fig.

CR4.1B). The left ventricular ejection fraction was normal. The patient underwent successful balloon angioplasty of the proximal circumflex artery, which arose from an independent ostium in the left anterior aortic sinus, adjacent to the separate ostium that gave rise to the LAD (absent left main trunk). ■

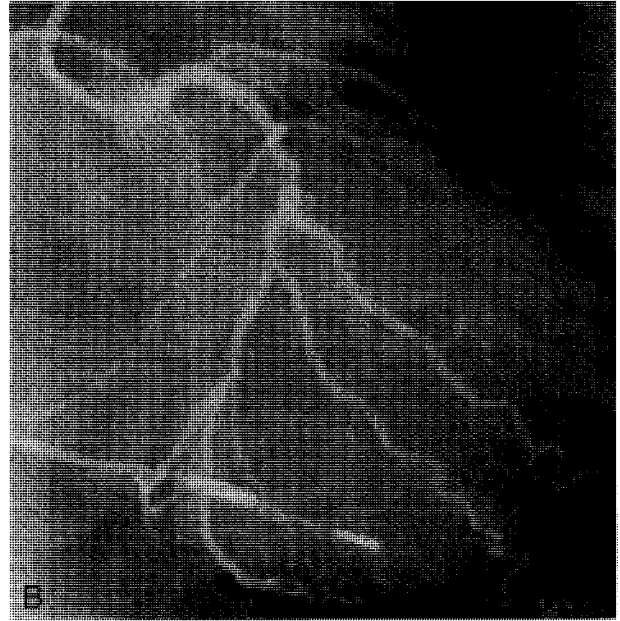
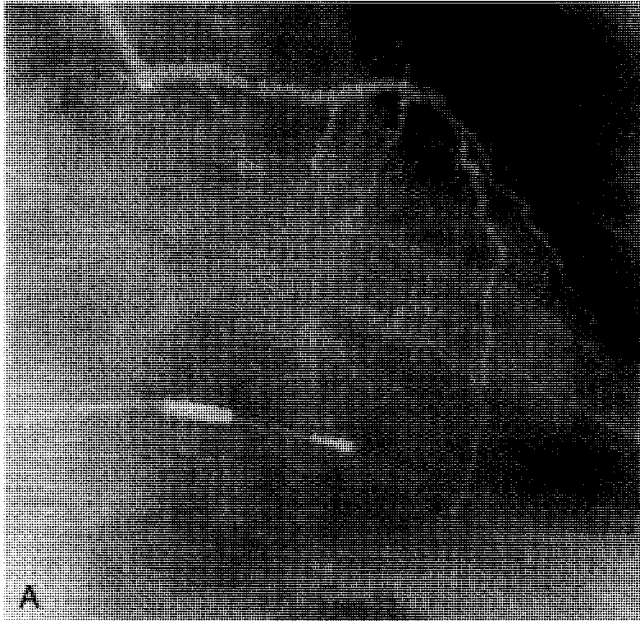


Figure CR4.1. A. Angiogram of the LAD in the right anterior oblique projection, showing diffuse coronary disease. B. Circumflex artery in the same projection. Note lack of visualization of the other LCA despite reflow of contrast material into the aorta.

CASE REPORT 4.2

Anomalous Location of the Coronary Ostium in the Appropriate Sinus: High Origination of the RCA

A 72-year-old man with diabetes mellitus and hypertension presented with recent-onset angina. The patient was a cigarette smoker and had a family history of coronary artery disease. A myocardial infarction was diagnosed. Cardiac catheterization revealed occlusion of the RCA, which had a high anterior origin

in the right sinus (Fig. CR4.2, A–C). The left coronary system filled the branches of the distal RCA by means of collateral vessels. Submaximal thallium exercise testing showed a nonreversible defect in the inferior ventricular wall. Continued medical treatment was recommended. ■

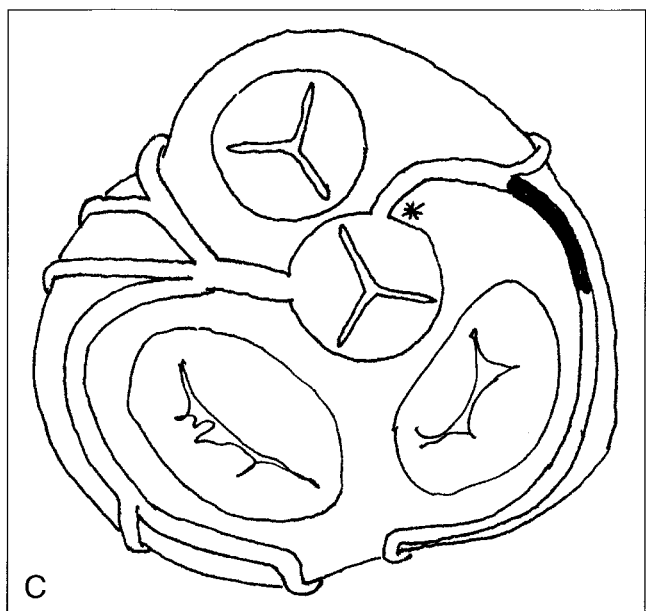
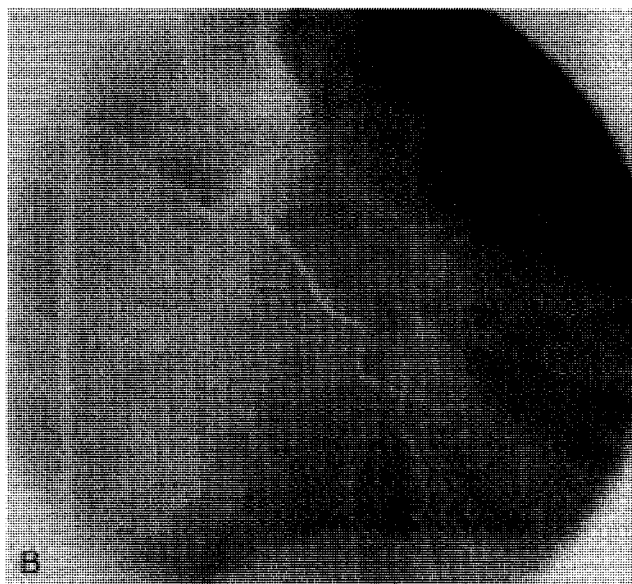
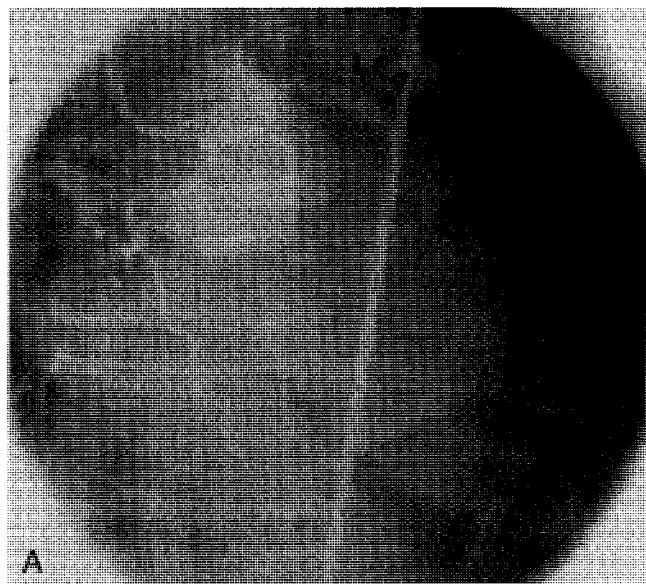


Figure CR4.2. Angiograms of the RCA in the left (A) and right (B) anterior oblique projections. The ostium has a high anterior origin, close to the anterior commissure. The vessel is totally occluded distal to an anterior ventricular branch. Contrast medium spills over into the left anterior cusp (L), from which the LCA originates. C. Schematic diagram of the coronary anomaly (coronal plane). * = Eccentric site of origin of the RCA, close to the anterior commissure.

CASE REPORT 4.3**Anomalous Location of the Coronary Ostium in, or Close to, the Appropriate Sinus: Low Origination of the RCA**

A 77-year-old woman with a previous history of coronary artery disease, myocardial infarction, and aortocoronary bypass surgery, presented with recurrent angina. Cardiac catheterization revealed 100% occlusion of the LAD and the RCA, which had a

low origin in the right coronary sinus (Fig. CR4.3). Two of the four previous bypass grafts were also occluded. On physical examination, no aortic valve murmur was heard. ■

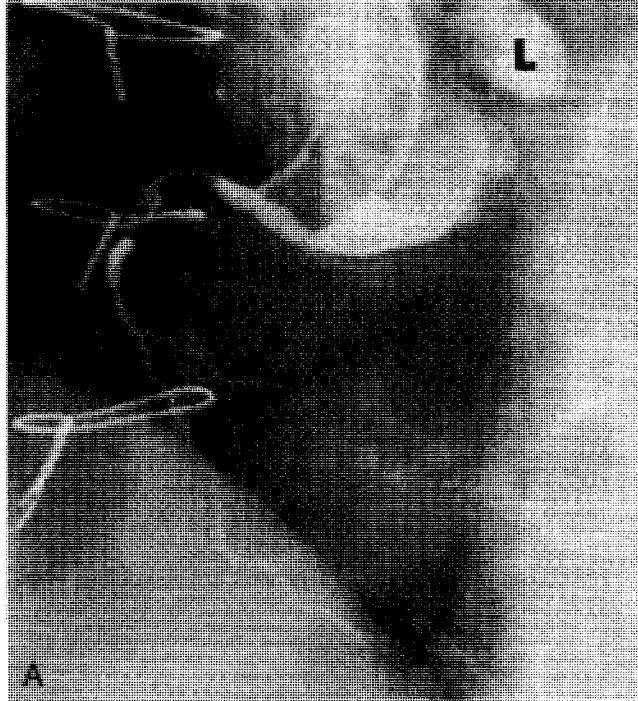


Figure CR4.3. Angiogram of the RCA in the left anterior oblique projection, showing a coronary ostium at the lower end of the coronary sinus. The aortic sinuses may be mildly asymmetric with a diminutive left anterior sinus (L). Figure 4.7 (see main text) shows a schematic diagram of the coronary anomaly.

CASE REPORT 4.4**Anomalous Location of the Coronary Ostium in, or Close to, the Appropriate Sinus: Low Origination of the RCA**

A 77-year-old woman presented with a 1-week history of intermittent chest pain that radiated to her left shoulder. The patient was a cigarette smoker with hypertension and severe aortic insufficiency, as well as a 1-year history of dyspnea and fatigue. Cardiac catheterization confirmed the presence of severe aortic insuf-

ficiency and normal coronary arteries with low origination of the RCA (Fig. CR4.4, A–B). The aortic regurgitation was assumed to be related to systemic hypertension, with dilation of the aortic annulus. For a diagram of a similar anomaly, see Figure 4.7. ■

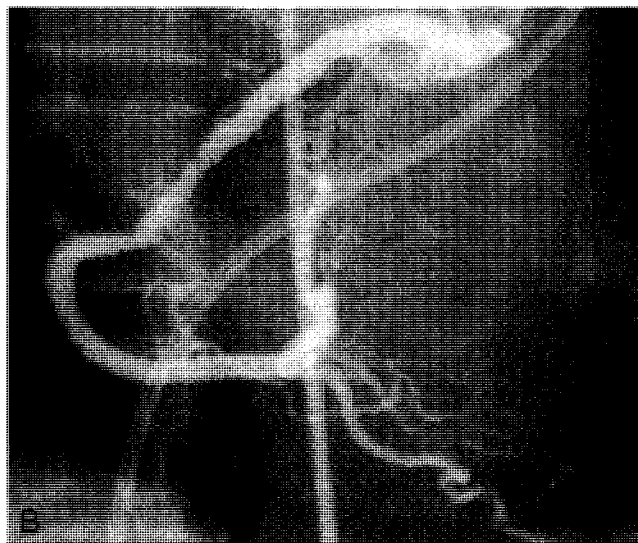
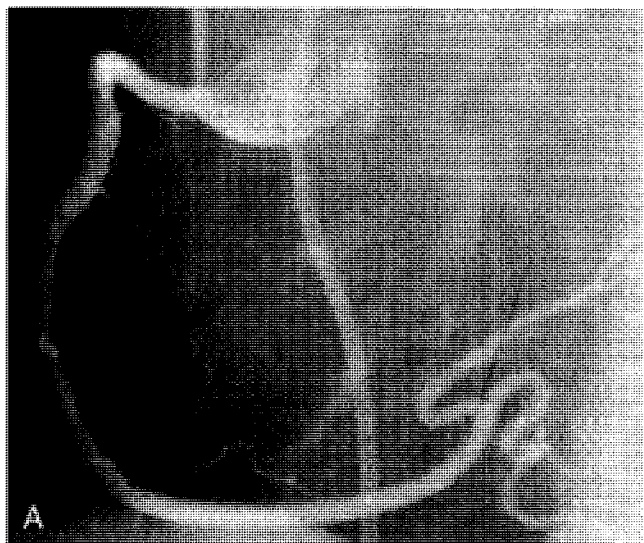


Figure CR4.4. Angiograms of the RCA in the left (A) and right (B) anterior oblique projections (see text).

CASE REPORT 4.5

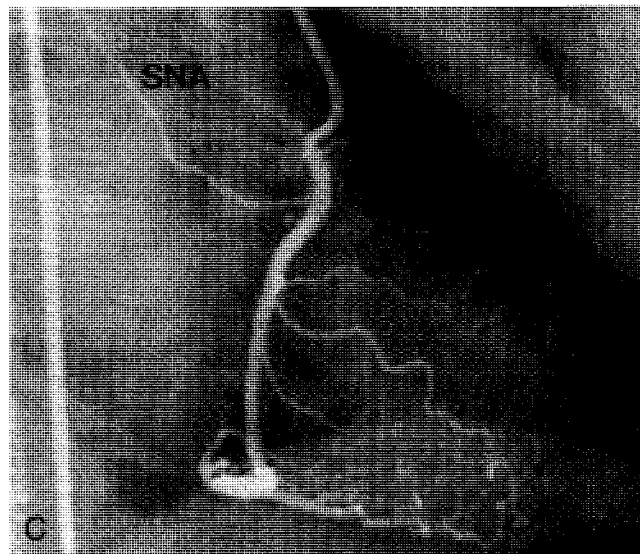
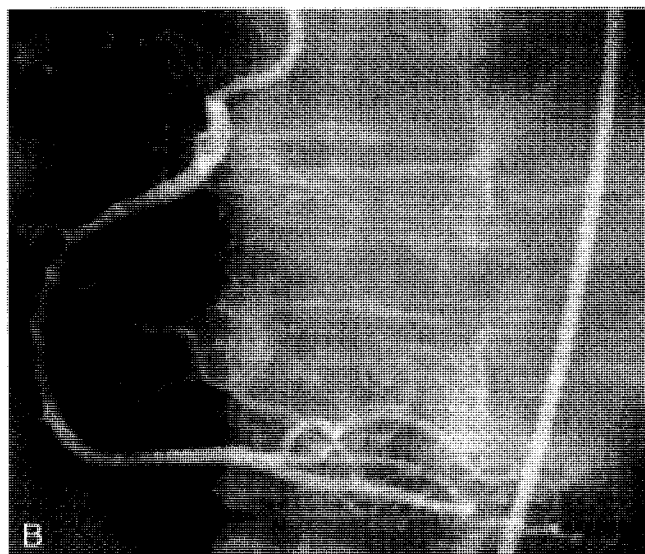
Anomalous Location of the Coronary Ostium in the Appropriate Sinus: Commissural Origination of the RCA

A 59-year-old woman with hypertension and coronary artery disease was admitted with Canadian Heart Association functional class-III angina. Cardiac catheterization showed a critical lesion in the LAD (at the site of previous percutaneous transluminal coronary angioplasty) and a dominant RCA, which had a com-

missural origin (Fig. CR4.5, A–C). Interestingly, the patient had ST-segment elevation and angina during selective catheterization and contrast injection at the RCA. It is likely that the ectopic RCA had a tangential proximal trunk with enhanced spasticity. Coronary vasodilator therapy was recommended. ■

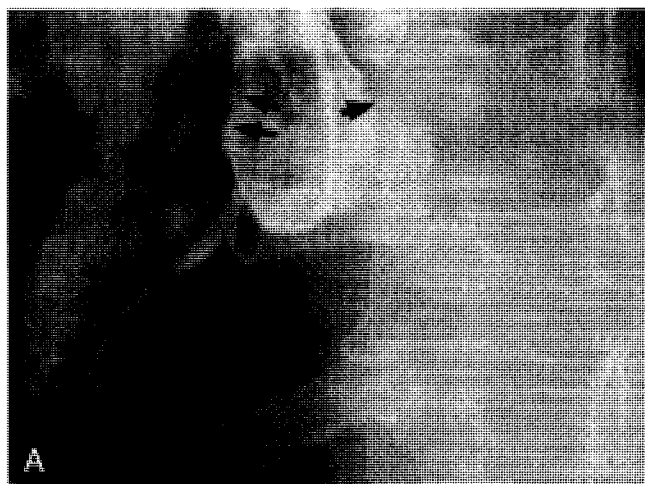

Figure CR4.5. A. Angiogram of the RCA in the left anterior oblique projection. A Judkins right coronary catheter could not selectively cannulate the ectopic artery but did reveal the ostium's unusual location in the posterior-most portion of the right anterior sinus. Single arrow = anterior commissure of the right anterior sinus of Valsalva; double arrows = posterior-right commissures of the right anterior sinus of Valsalva. B and C. After the angina resolved, selective angiograms of the RCA in the posteroanterior (B) and right anterior oblique (C) projections showed a normal luminal size. Selective catheterization was achieved with an Amplatz-I right coronary catheter. Initial attempts to cannulate the RCA with a noncoaxial catheter may have resulted in ostial spasm (not documented on cineangiography). SNA = sinus node artery.



CASE REPORT 4.6**Anomalous Location of the Coronary Ostium in, or Close to, the Appropriate Sinus: Commissural Origination of the RCA**

A 41-year-old man presented with new-onset angina and abnormal thallium stress test results indicating an inferior, reversible defect. On physical examination, no heart murmur was heard. Cardiac catheterization revealed “absence” of the LAD, as well

as commissural origination of the RCA and the right aortic arch (Fig. CR4.6, A–C). The stress test was deemed false positive, and medical treatment was continued. ■

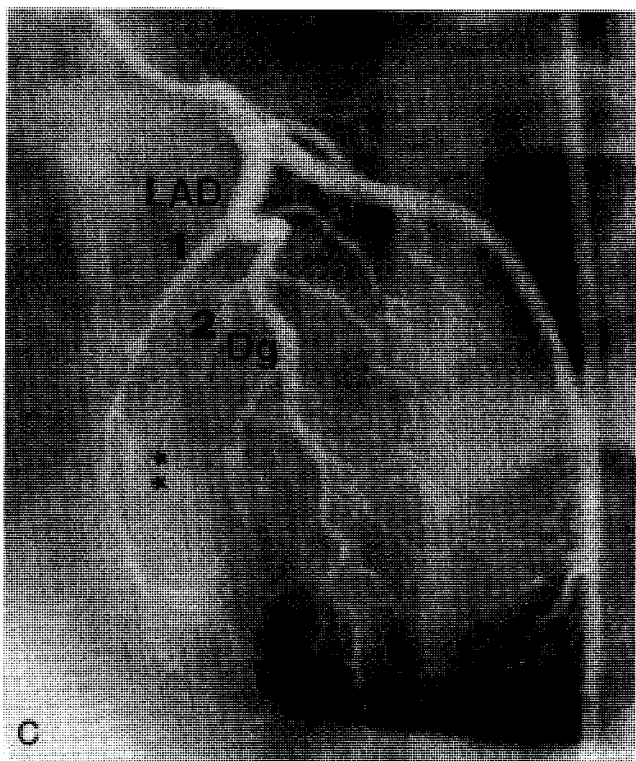
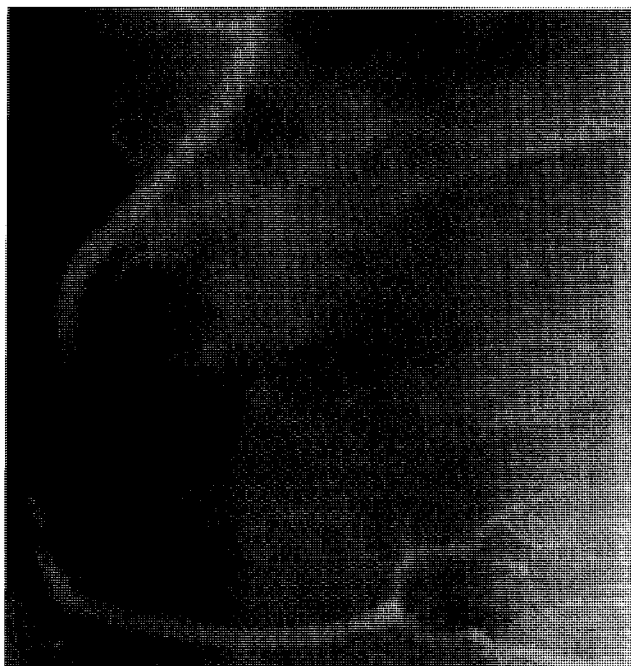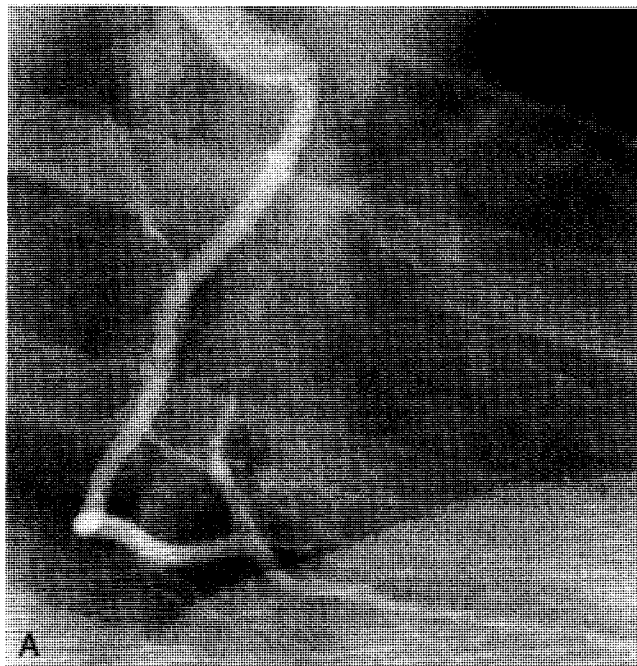


Figure CR4.6. Angiogram of the RCA, in the right (A) and left (B) anterior oblique projections, showing the ostium located above the commissure, between the right and left anterior sinuses. The right sinus seems larger than the left one, but no specific study was carried out to confirm the presence of asymmetry. In view A, the RCA pursues a direct course down to the right atrioventricular groove, and spilled-over contrast material fills the neighboring right coronary sinus. Both features suggest commissural (versus left sinus) origination of the RCA. In view B, the asterisk indicates the peak of the anterior commissure, and the dotted lines indicate the intercusp space or triangle. C. Angiogram of the LCA in the left anterior oblique projection. The LAD is present only as far as the bifurcation of the second septal branch. The LAD continues into a large epicardial vessel (Dg), which lies lateral to the anterior interventricular groove (asterisks), and should be called the diagonal artery (absent distal epicardial LAD). 1 = first septal branch; 2 = second septal branch.

CASE REPORT 4.7

Anomalous Location of the Coronary Ostium in, or Close to, the Appropriate Sinus: High Posterior Origination of the LCA

A 53-year-old man with hypertension and obesity was admitted for exertional epigastric discomfort and dyspnea. Cardiac catheterization showed diffuse coronary ectasia but no obstructive cor-

onary artery disease (Fig. CR4.7, A–F). The left ventricular ejection fraction was normal. Continued medical treatment was recommended. ►

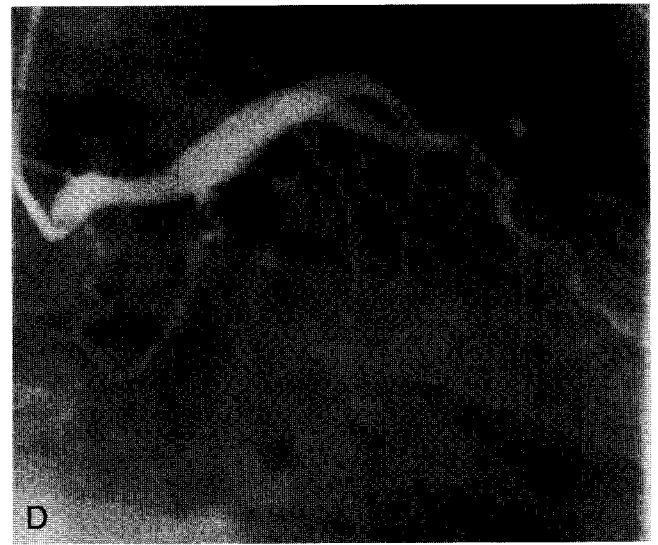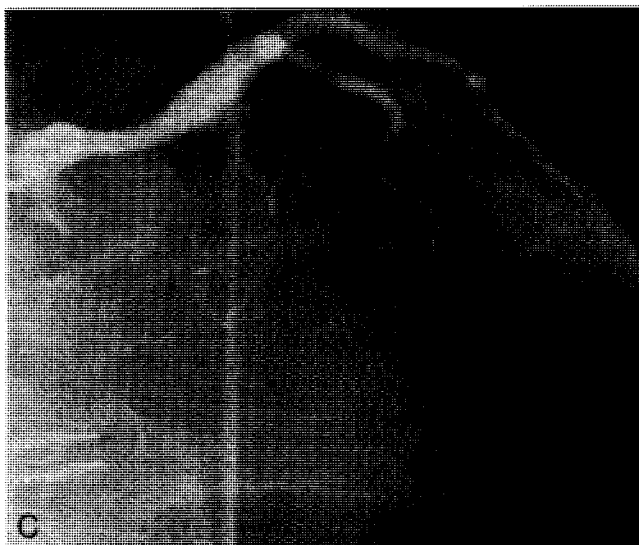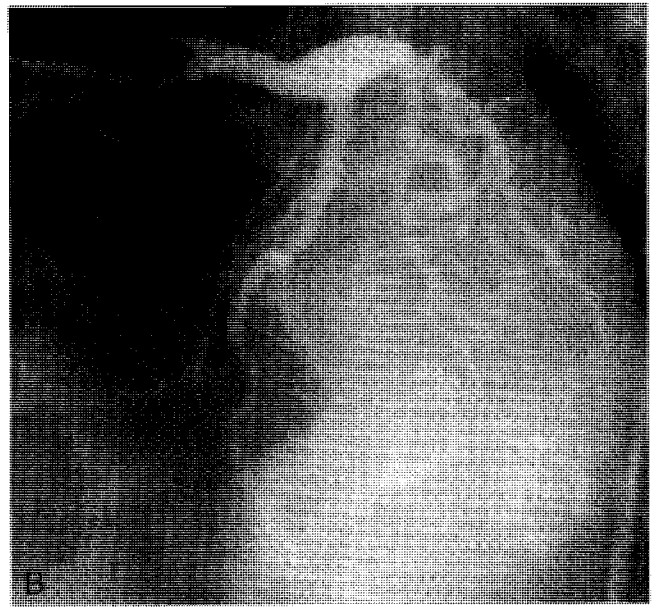
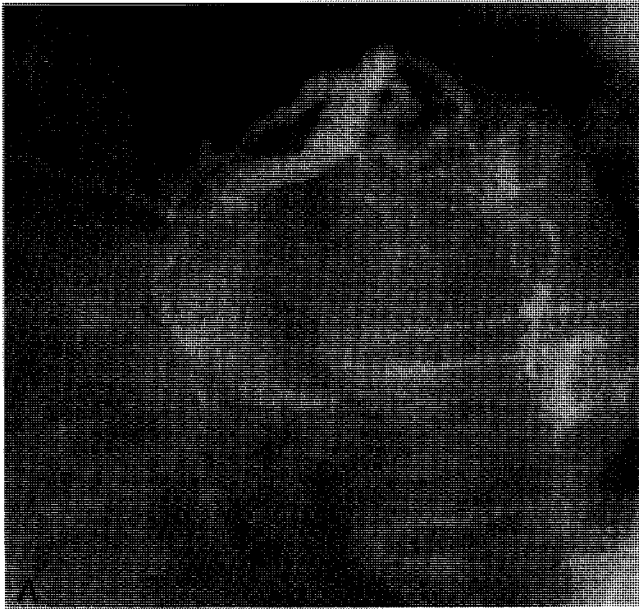


Figure CR4.7. Angiograms of the LCA in the caudal left anterior oblique (A), cranial left anterior oblique (B), posteroanterior (C), and right anterior oblique (D) projections. (continued)

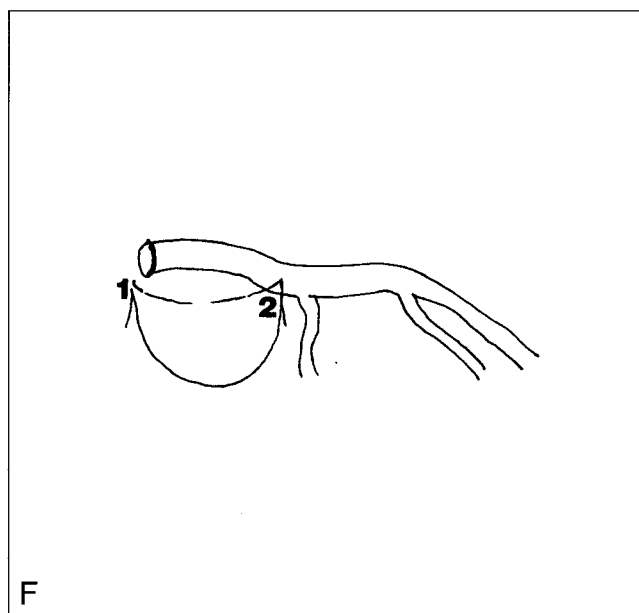
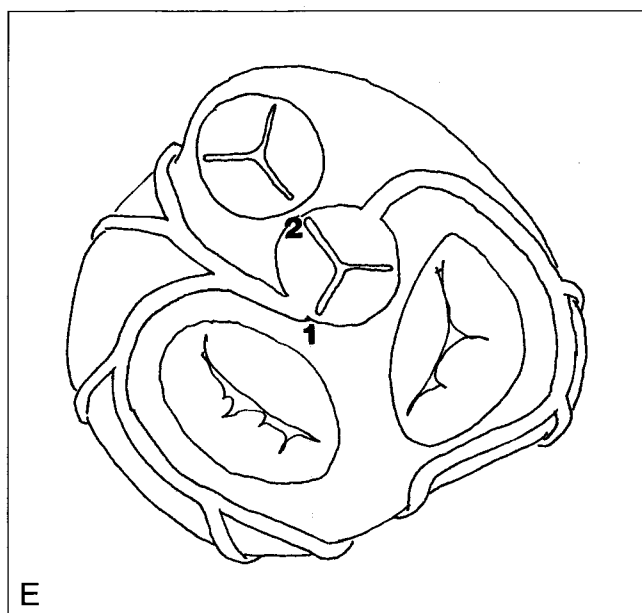


Figure CR4.7. (Continued) **E.** In this schematic diagram, imaged in the coronal plane, the LCA originates close to the posterior commissure (1) of the coronary sinus and away from the anterior commissure (2). **F.** This schematic diagram, imaged in the sagittal plane, shows the ostial location in its vertical relationship to the left coronary sinus.

CASE REPORT 4.8

Anomalous Location of the Coronary Ostium Outside the Normal "Coronary" Sinuses: LCA Origination From the Right Posterior ("Noncoronary") Sinus and RCA Origination From the Left Anterior Sinus

A 61-year-old man with hypertension and dilated cardiomyopathy was admitted to our institution for evaluation. Cardiac catheterization showed that the LCA originated from the posterior sinus and the RCA originated from the left anterior sinus (Fig.

CR4.8, A-C). On physical examination, no heart murmur was heard. The coronary anomalies were considered to be unrelated to the cardiomyopathy, and continued medical treatment was recommended. ■

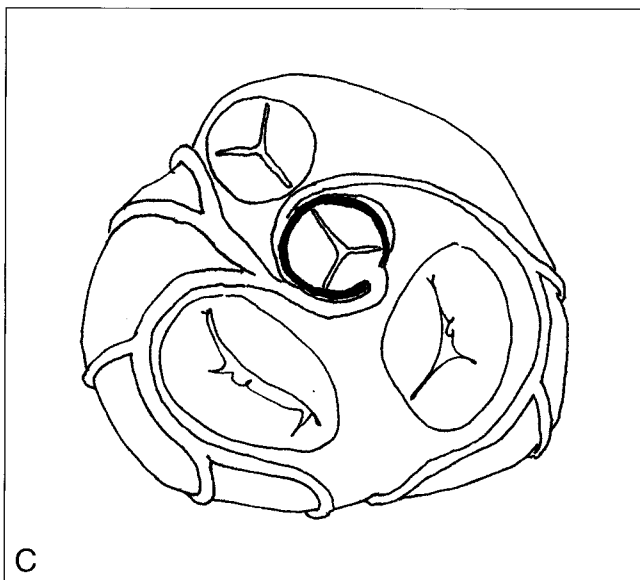
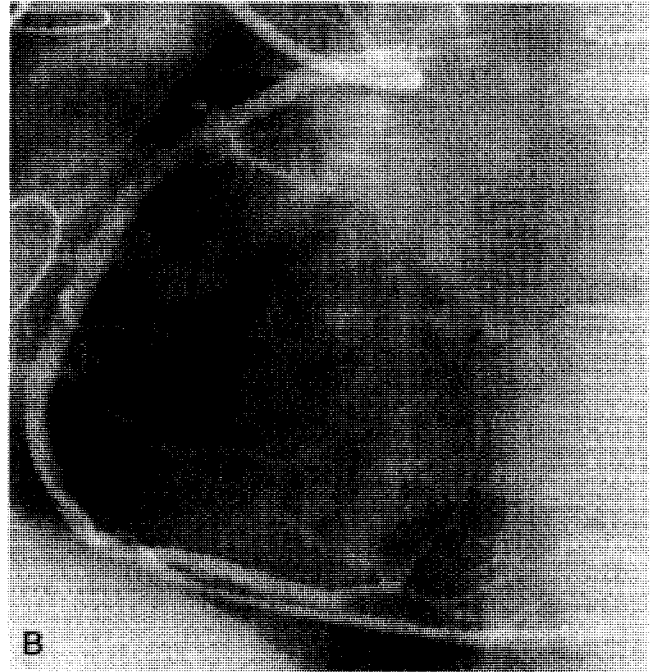
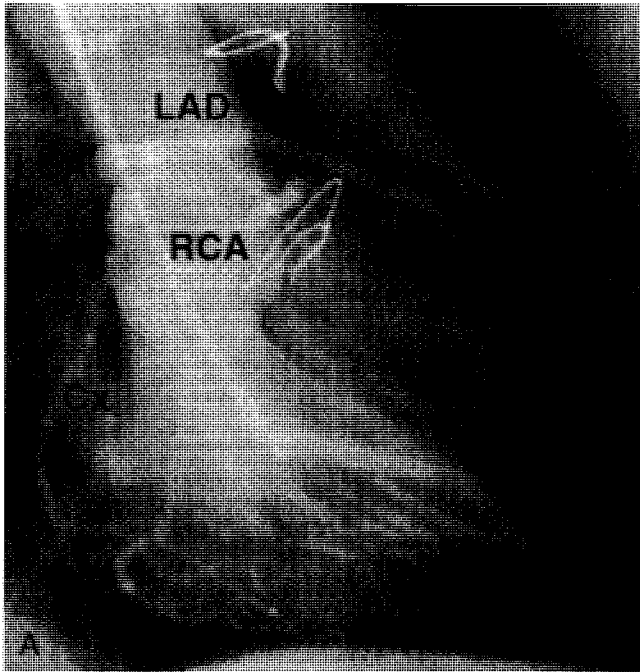


Figure CR4.8. **A.** Left ventriculogram, in the right anterior oblique projection, showing the anomalous coronary morphology: the proximal LCA originates posterior to the aorta, above the aortic sinus level, and the RCA originates lower, from the left anterior sinus. Cx = circumflex artery; LAD = left anterior descending artery. A selective left coronary angiogram (not shown) confirmed the origination of the LCA from a site above the noncoronary sinus. **B.** Selective angiogram of the RCA, showing associated ectopy of the LCA, which originates from the left coronary sinus. **C.** In this schematic diagram of the anomaly, both coronary arteries, at their origins, seem to be rotated 120° counterclockwise with respect to normal. The LCA originates above the usual level inside the aortic root. The dark circle above the aortic valve represents the sinotubular junction.

CASE REPORT 4.9

Anomalous Location of the Ectopic Coronary Ostium Outside the Normal “Coronary” Sinuses: Origination of the Circumflex Artery From the Right Posterior (“Noncoronary”) Sinus and Absent Left Main Trunk

A 70-year-old man with hypertension, hyperlipidemia, and a previous myocardial infarction presented with progressive angina. Cardiac catheterization showed triple-vessel coronary obstructive disease and diffuse hypokinesia (Fig. CR4.9, A and B). The circumflex artery originated separately and anomalously from the

posterior aortic sinus (Fig. CR4.9, C). The LAD originated independently from the left aortic sinus, so this case involved an absent left main trunk. Aortocoronary artery bypass surgery was successfully carried out. ■

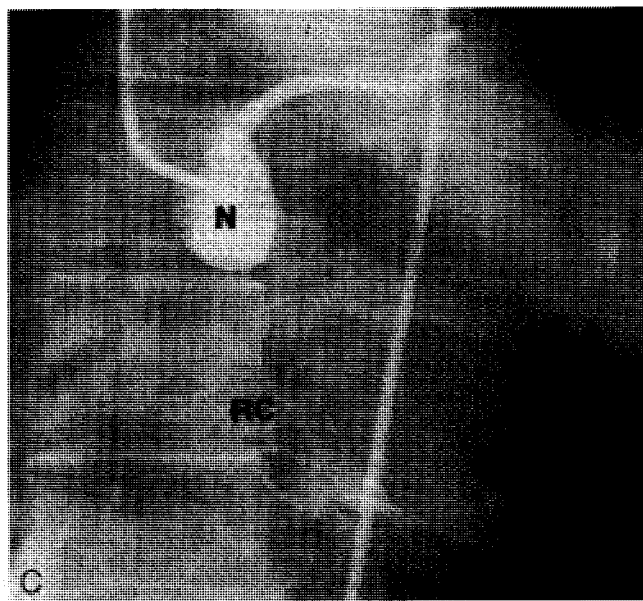
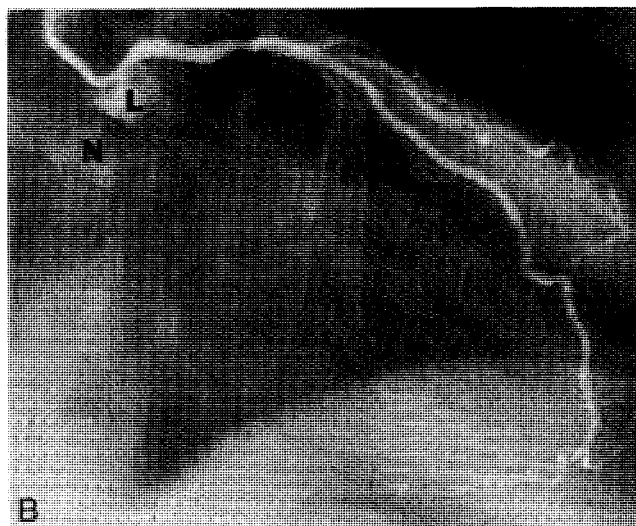
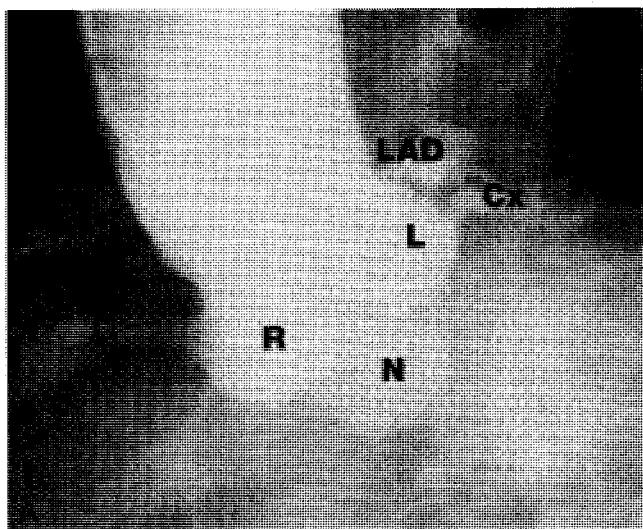


Figure CR4.9. A. Aortogram in the left anterior oblique projection. This image suggests, but does not prove, the absence of a left main trunk. The aortic sinuses are grossly equal in size. Cx = circumflex artery; L = left; LAD = left anterior descending artery; N = noncoronary sinus; R = right sinus. B. Selective angiogram of the LAD, in the right anterior oblique projection, showing the artery's isolated origination from the left coronary sinus (L). N = noncoronary sinus. C. Nonselective angiographic visualization of the circumflex artery, in the posteroanterior projection, showing that this artery originates from the noncoronary sinus (N), independently of the LAD. The distal RCA (RC) is filled via collateral vessels from the circumflex artery.

CASE REPORT 4.10

Anomalous Location of the Coronary Ostium in the Ascending Aorta

A 70-year-old man with diabetes mellitus was admitted because of exertional angina that was relieved by rest. Cardiac catheterization showed that the RCA originated ectopically from the ascending aorta, some 4 cm above the left coronary sinus (Fig.

CR4.10, A–D). It also showed nonobstructive plaques in the proximal LAD. Left ventricular systolic function was normal. The patient's angina improved with beta-blocking drugs. ■

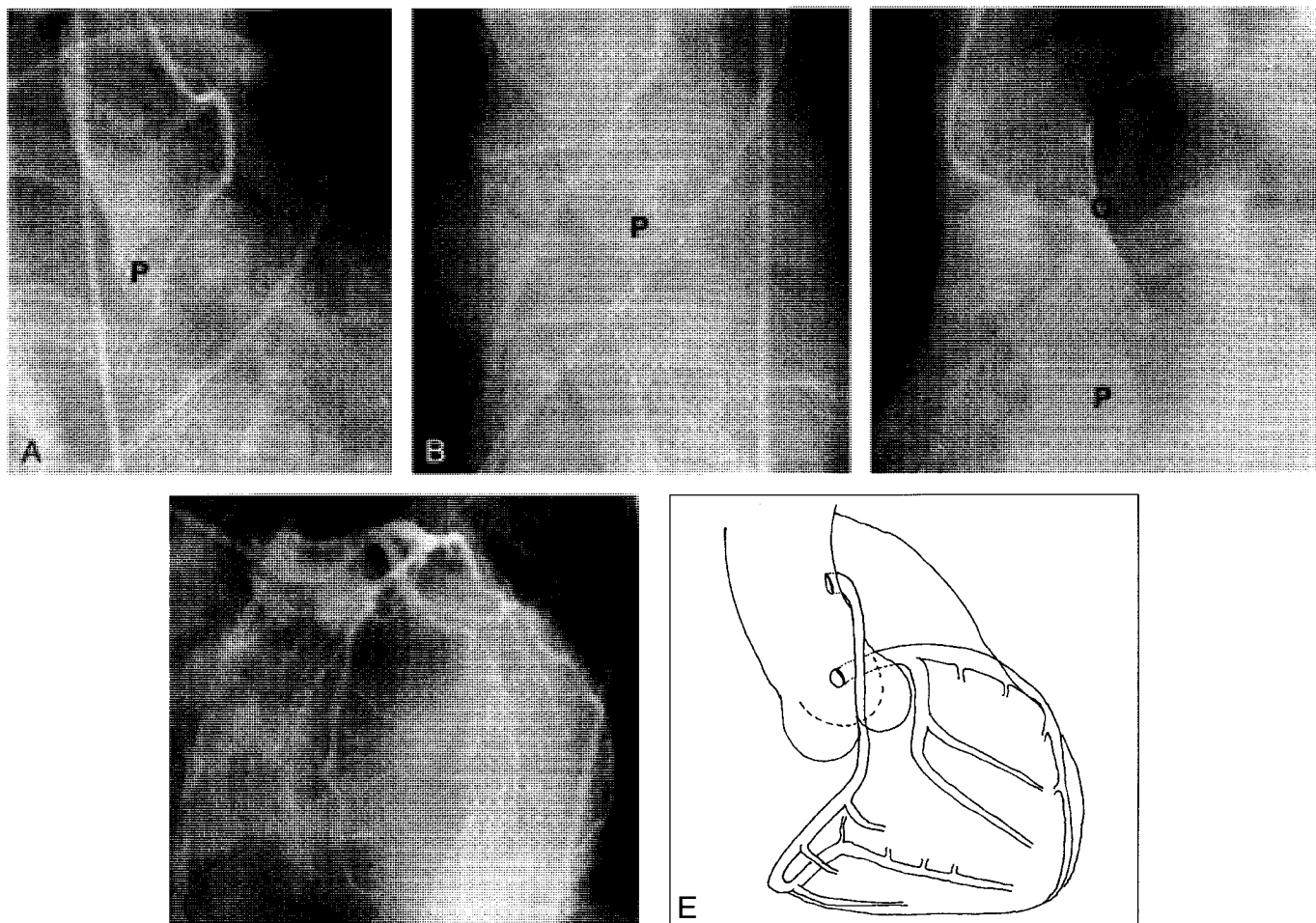


Figure CR4.10. Angiograms of the RCA in the right anterior oblique (A), posteroanterior (B), and left anterior oblique (C), projections, showing origination of the RCA from the ascending aorta, some 4 cm above the left coronary sinus (P = posterior sinus; O = coronary ostium). D. Angiogram of the LCA in the left anterior oblique projection, showing normal angiographic features. E. Diagrammatic representation of the coronary anomaly (right anterior oblique view).

CASE REPORT 4.11**Anomalous Location of the Coronary Ostium Outside the Normal “Coronary” Sinuses: Origination of the LCA From the Pulmonary Artery**

A 26-year-old woman with dyspnea and atypical chest pain was admitted for cardiac evaluation. Physical examination disclosed a continuous murmur at the left sternal border. Transesophageal Doppler echocardiography showed a dilated RCA, with an abnormal vessel showing a high-velocity flow signal and draining into the pulmonary artery. Moderate, diffuse left ventricular hypokinesia (ejection fraction, 35%) was also present. Catheterization

showed that the LCA originated anomalously from the posterior sinus of the pulmonary artery; a significant oxygen step-up was present, with a calculated pulmonary-to-systemic flow ratio of 1.9:1. The LCA was reimplanted directly into the aortic root, and the pulmonary artery was repaired with an expanded polytetrafluoroethylene patch. ►

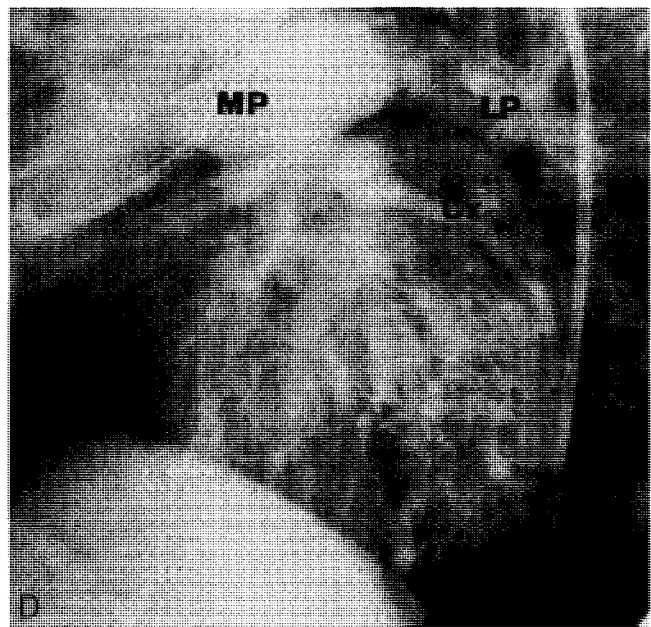
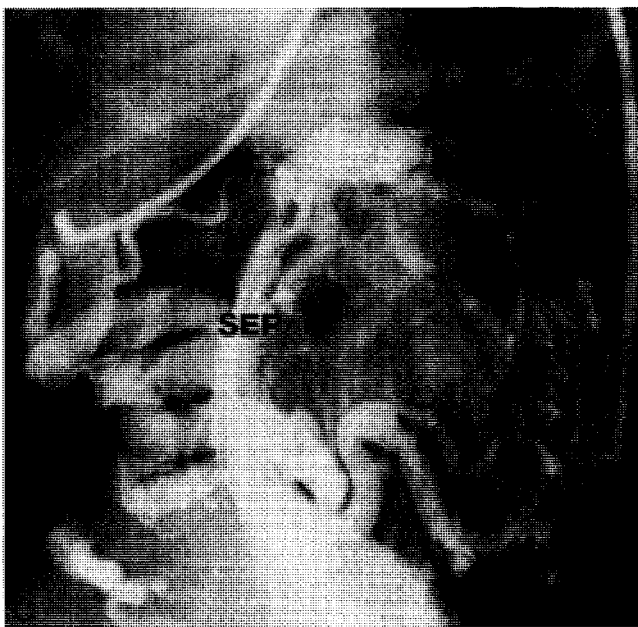
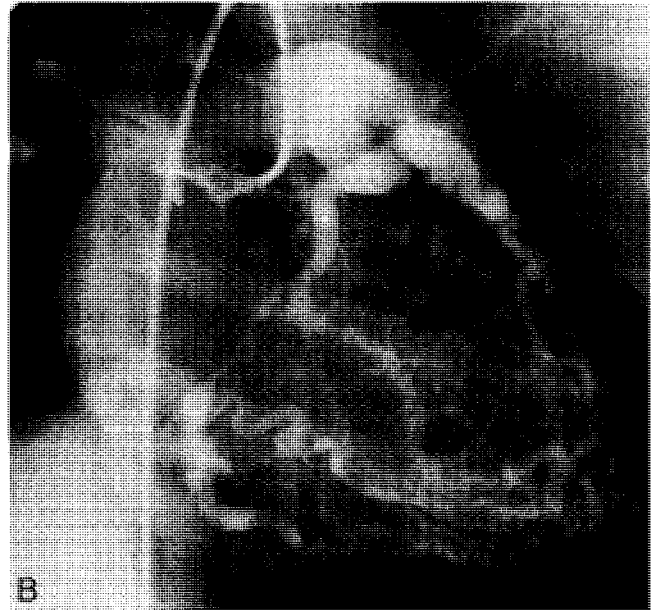
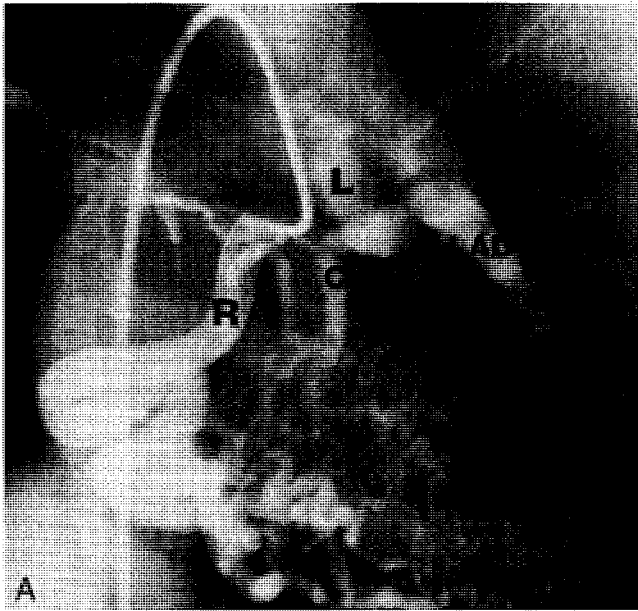


Figure CR4.11. See legend on next page

CASE REPORT 4.12**RCA Arising From the Left Anterior Sinus: “Single Left Coronary System” with the RCA Arising From the Distal Circumflex Artery and Following a Posterior Course**

A 29-year-old man, with a history of insulin-dependent diabetes mellitus and cigarette smoking, was admitted for exertional angina, diaphoresis, and dyspnea. At age 5 years, he had undergone surgical repair of a patent ductus arteriosus and pulmonic stenosis. During the present admission, echocardiography revealed an atrial septal defect, mild pulmonary hypertension, and moderate pulmonary insufficiency. Cardiac catheterization confirmed these findings and showed that the LCA was anomalous

(it indeed had a mixed proximal trunk) because it produced not only the LAD and the circumflex arteries but also all of the right coronary branches, including the posterior descending artery and the anterior infundibular (terminal) branches (Fig. CR4.12, A and B). The RCA arose from the distal circumflex artery and followed a posterior course. Elective closure of the atrial septal defect was recommended but has not yet been carried out. ■

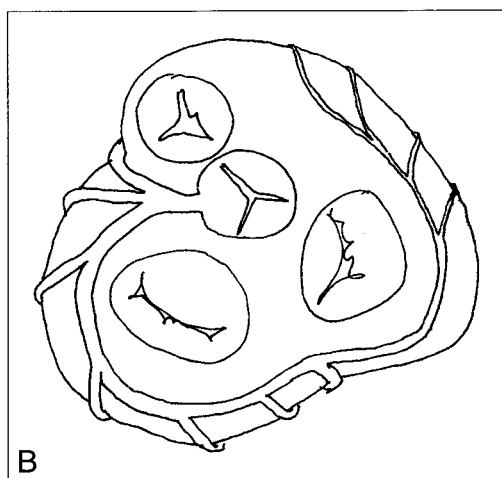
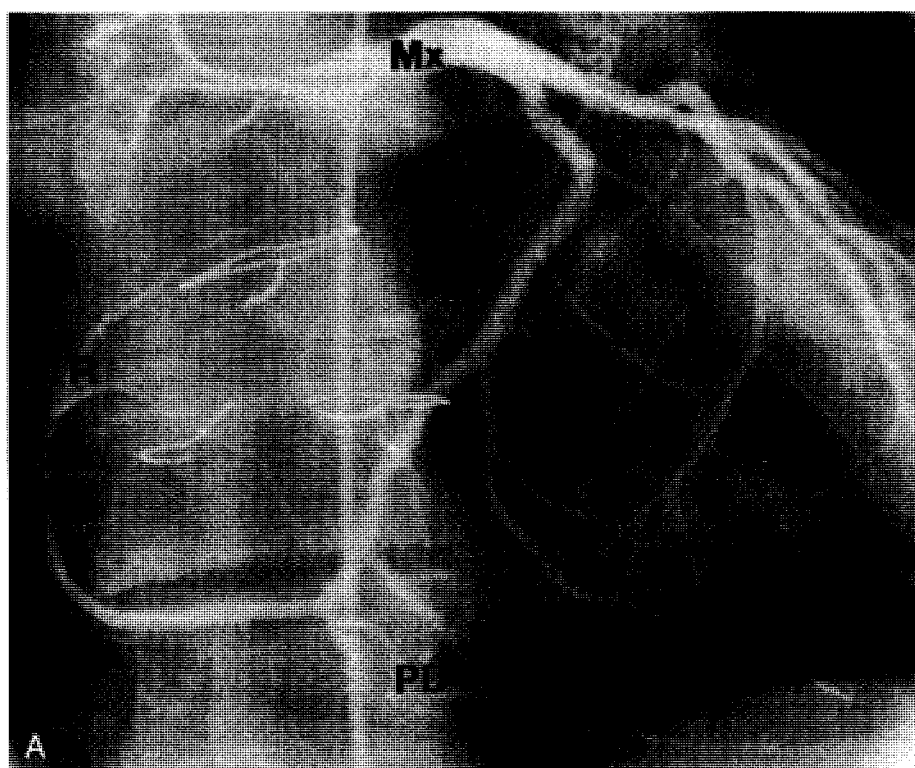


Figure CR4.12. A. Angiogram of the LCA in the posteroanterior projection (see text). Mx = mixed proximal trunk; PD = posterior descending artery; R = terminal RCA branches. B. Schematic diagram of the coronary anomaly (coronal plane).

CASE REPORT 4.13

Single Coronary Artery: RCA Arising From the Distal Circumflex Artery and Following a Posterior Course

A 48-year-old woman underwent coronary angiography for atypical chest pain. Treadmill exercise testing had yielded inconclusive results. Coronary angiography (Fig. CR4.13, A–C) revealed a single coronary artery that originated in the left anterior aortic sinus; the RCA arose as a continuation of the left circumflex ar-

tery in the right atrioventricular groove. The anterior right ventricular artery originated from the proximal LAD and coursed anterior to the pulmonary infundibulum, representing an anomaly in itself. The RCA's terminal branch was the sinus node artery. Continued medical treatment was recommended. ■

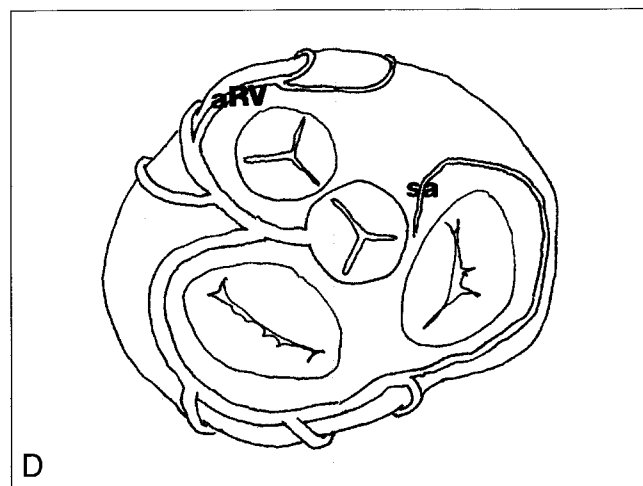
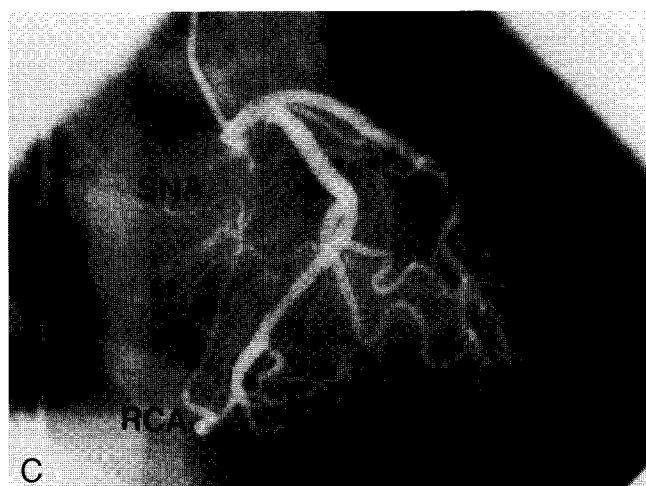
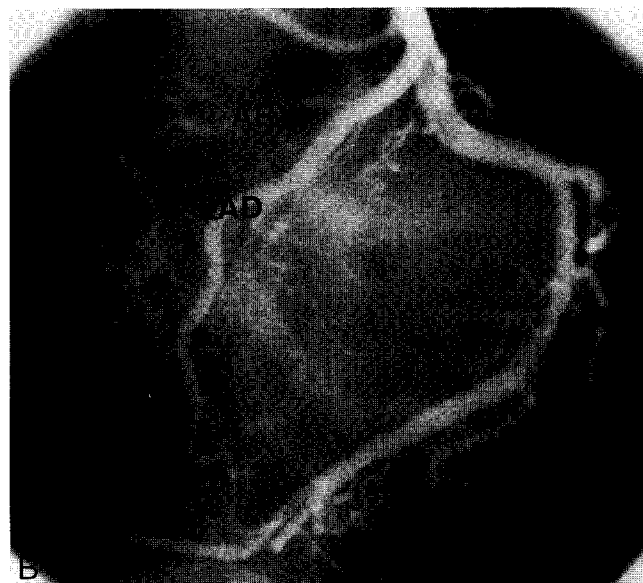
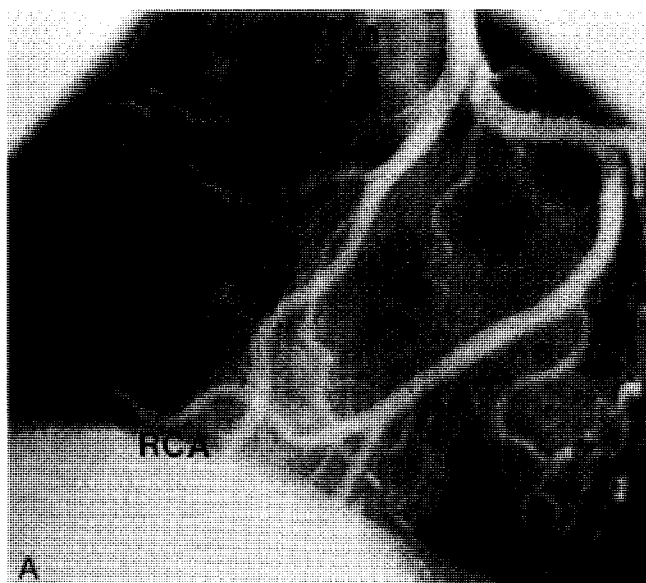


Figure CR4.13. Angiograms of the left coronary artery in the cranial left anterior oblique (A), left anterior oblique (B), and right anterior oblique (C) projections (see text). The anterolateral free wall of the right ventricle is supplied essentially by LAD-originating branches (ARV): Is this a case of split RCA? The distal circumflex extends to the right of the posterior descending branch and terminates in the sinus node artery (SNA). D. Diagrammatic representation of the anomaly in the coronal plane. aRV = anterior right ventricular branch; sa = sinus node artery.

CASE REPORT 4.14

Anomalous Location of the Coronary Ostium in the Opposite Sinus: Circumflex Artery Arising From the Right Anterior Sinus (Mixed Trunk) and Following a Retrocardiac Course Behind the Atrioventricular Valves

A 70-year-old man, with a history of hypertension, cigarette smoking, diabetes mellitus, and coronary artery disease, presented with unstable angina. Cardiac catheterization revealed nonobstructive plaques in the LAD and the diagonal artery; the LAD was the only vessel to originate from the left sinus (Fig. CR4.14A). The territories of the circumflex and obtuse marginal arteries were supplied by terminal branches of the "RCA:" the

proximal coronary artery, which arose from the right sinus, was actually a mixed trunk (producing the RCA and the circumflex artery) until it passed the cardiac crux and the posterior descending artery (Fig. CR4.14, B and C). After that point, it became an anomalous circumflex artery with two large obtuse marginal branches. Continued medical treatment was recommended. ■

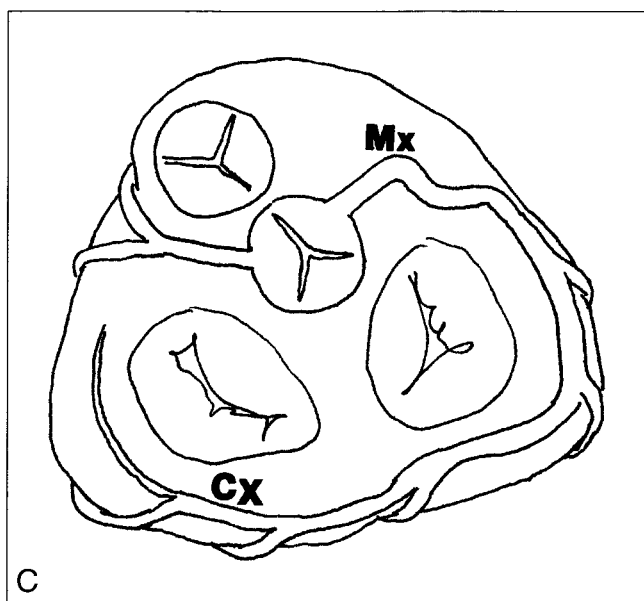
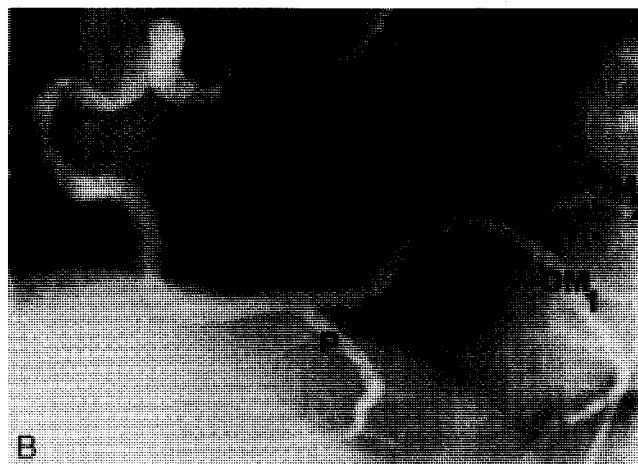
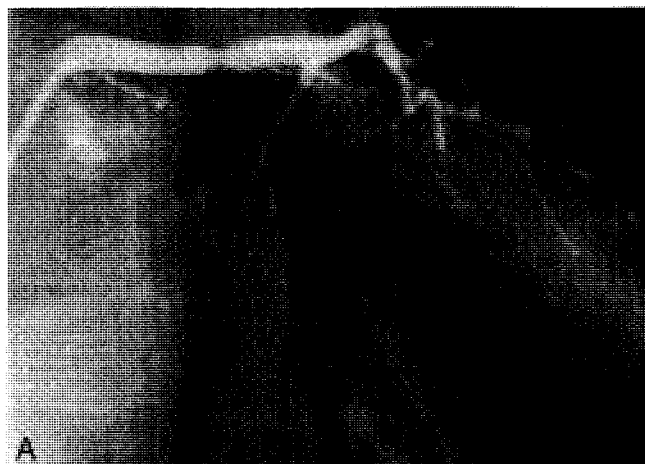


Figure CR4.14. A. Angiogram of the LAD in the right anterior oblique projection. B. Angiogram of the right-sided coronary vessel in the left anterior oblique projection. This highly dominant vessel produces not only the posterior descending artery (P) but also two obtuse marginal (OM) branches. The implication is that the circumflex artery is the terminal branch of a mixed trunk, composed of the RCA and the circumflex. C. Schematic diagram of the coronary anomaly (coronal plane). cx = circumflex artery; Mx = mixed proximal trunk.

CASE REPORT 4.15**Anomalous Location of the Coronary Ostium in the Opposite Sinus: Circumflex Artery Arising From the Right Anterior Sinus and Following a Retroaortic Path**

A 45-year-old man with a history of hypertension, smoking, hyperlipidemia, and chronic angina presented with unstable angina. The patient had a family history of coronary artery disease. Cardiac catheterization showed nonobstructive plaques in the proximal circumflex artery, which originated from the right coronary sinus and had a dominant pattern (Fig. CR4.15, A and B). An obtuse marginal branch also had a significant lesion. The RCA was

nondominant, essentially serving only the free wall of the right ventricle (Fig. CR4.15, C). The left coronary ostium provided flow only to the large diagonal (ramus) branch (Fig. CR4.15, D and E). The LAD was totally occluded at its origin from the left-sided artery, and filling occurred via collateral vessels. Aortocoronary bypass surgery was recommended. ►

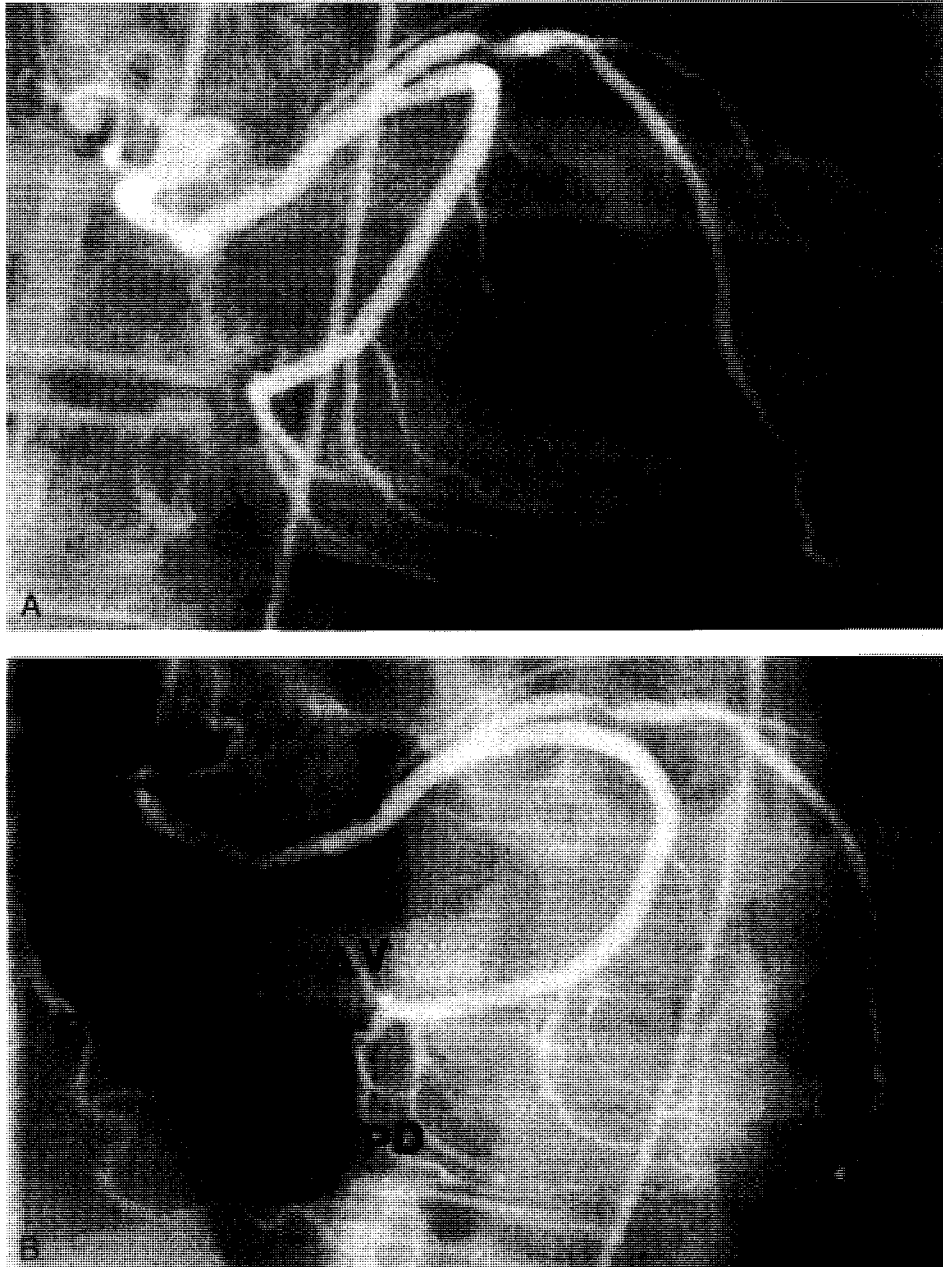


Figure CR4.15. See legend on next page.

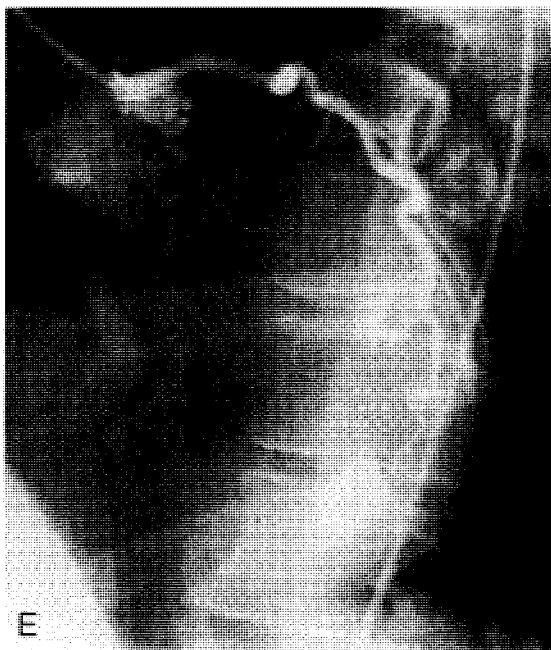
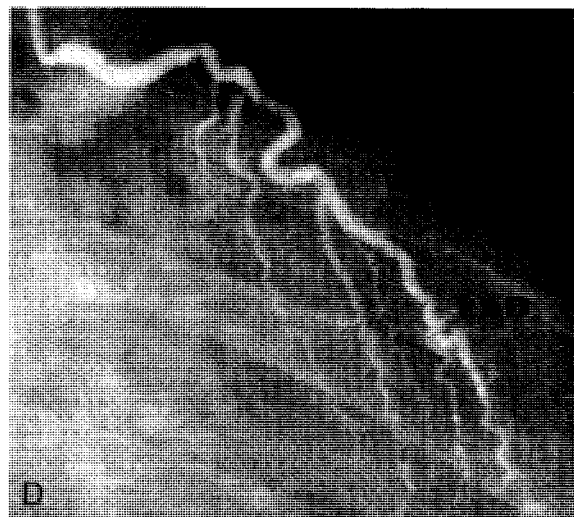
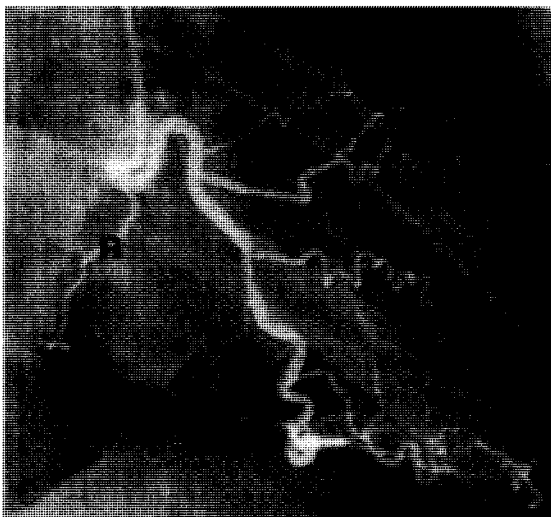


Figure CR4.15. Angiograms of the circumflex artery in the posteroanterior (**A**) and left anterior oblique (**B**) projections, showing origination of the posterior descending (PD) and atrioventricular node (AV) arteries from the distal vessel. The RCA (R), which has an adjoining ostium, is also visible. **C.** On selective injection, the RCA (R) appears as a small, nondominant vessel in the atrioventricular groove; a large anterior right ventricular branch also provides collaterals to the LAD. Right (**D**) and left (**E**) anterior oblique views of the left-sided artery, showing a stump of the LAD (view **D**; arrow, view **E**) and a large diagonal (ramus) branch.

CASE REPORT 4.16**Anomalous Location of the Coronary Ostium in the Opposite Sinus: Circumflex Artery Arising From the Right Anterior Sinus**

A 72-year-old man with hypercholesterolemia and a recent myocardial infarction was admitted for postinfarction angina. Electrocardiography showed sinus bradycardia, with tall R waves in leads V₁ to V₃ that suggested a posterior infarct. Coronary angiography indicated that the circumflex artery arose independently from the right anterior sinus and contained a 95% proximal stenosis (Fig. CR4.16, A); this artery supplied obtuse marginal branches 1 and 2. Angioplasty of the circumflex artery resulted

in moderate improvement (Fig. CR4.16, B). Use of an 8F multi-purpose catheter tended to cause ostial spasm and wedging. The circumflex artery supplied obtuse marginal branches 1 and 2.

Comment: In general, use of a catheter with side holes does not prevent catheter-induced spasm; moreover, the side holes allow monitoring only of the aortic pressure, not of the pressure at the tip of the guiding catheter. ■

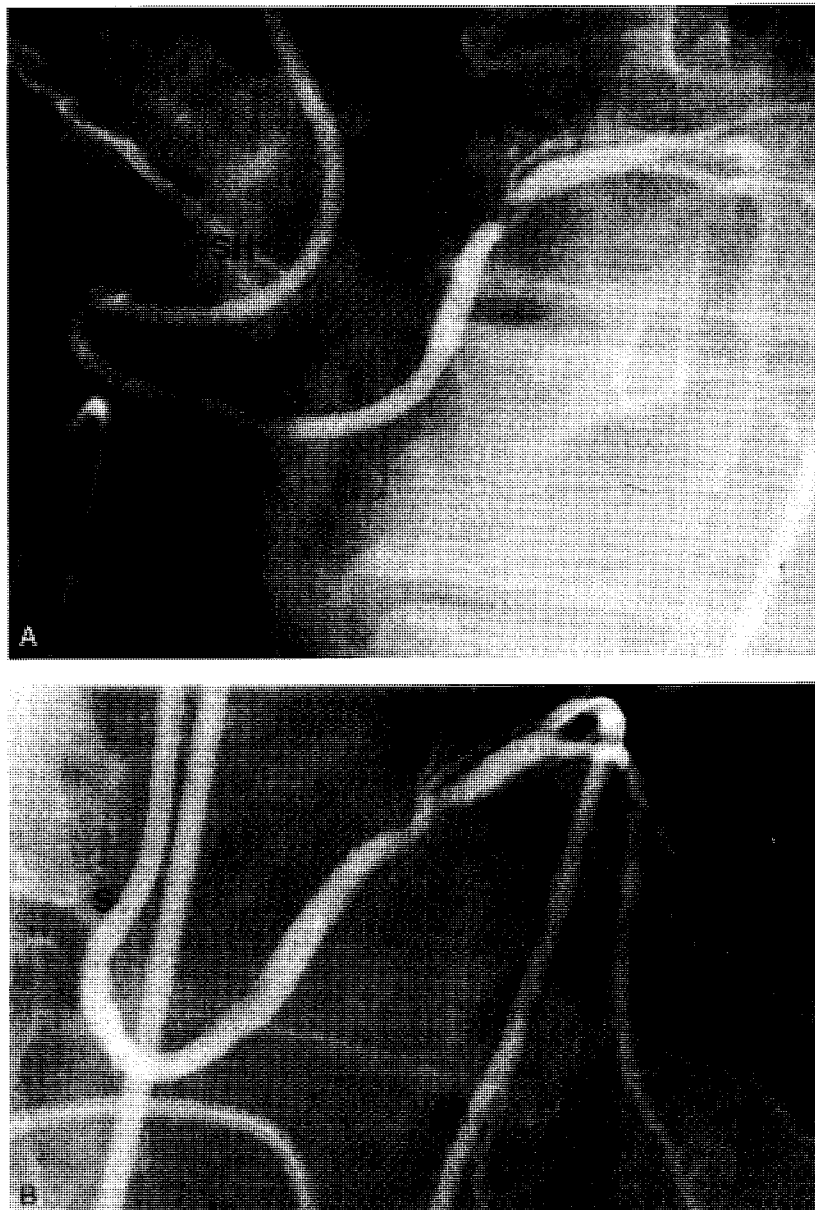


Figure CR4.16. Angiograms of the circumflex artery obtained (A) before angioplasty (left anterior oblique view) and (B) after angioplasty (right anterior oblique view) (see text). Both views show ostial spasm and wedging. S, SH = side-hole catheter.

CASE REPORT 4.17**Anomalous Location of the Coronary Ostium in the Opposite Sinus: Circumflex Artery Arising From the Right Anterior Sinus and Following a Retroaortic Path**

A 34-year-old man with a history of hypertension was admitted for the evaluation of atypical nonexertional chest pain. A resting nuclear scan showed a defect in the inferoposterior portion of the left ventricle. At cardiac catheterization, no coronary artery disease was present, but the circumflex artery originated abnormally from the right coronary sinus and followed a retroaortic path; there was no left main trunk proper (Fig. CR4.17, A–D).

The patient had evidently had a false positive nuclear stress test in the presence of normal coronary circulation. The hypothesis that he had had a previous myocardial infarction related to the anomalous path of the circumflex artery could not be supported by the clinical history, the electrocardiogram, or ventricular function studies. No intervention was necessary. ■

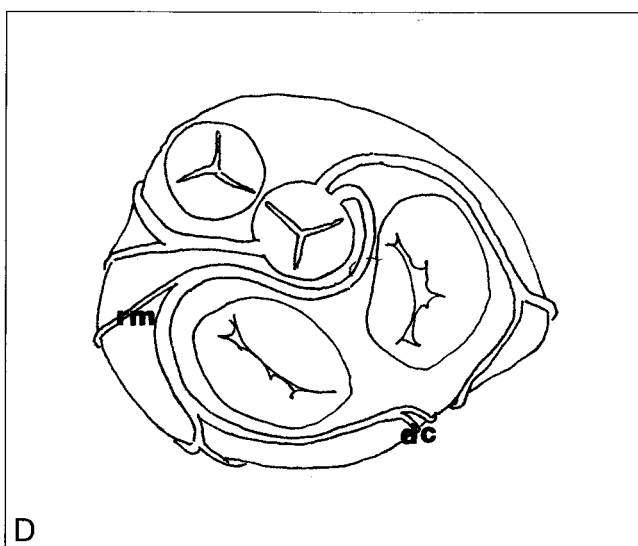
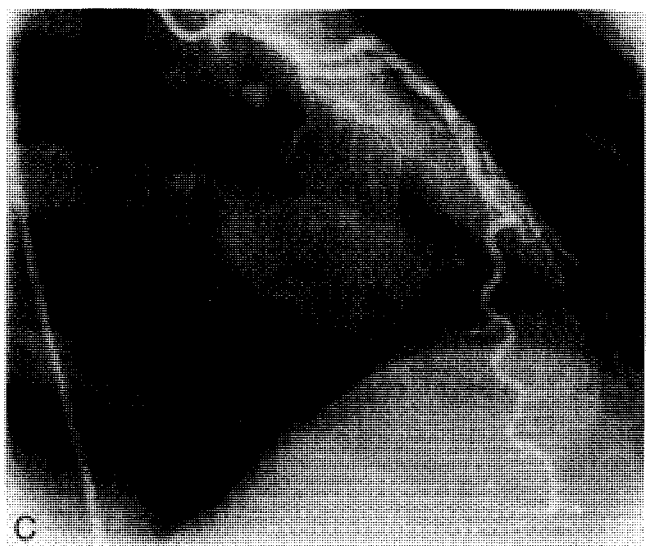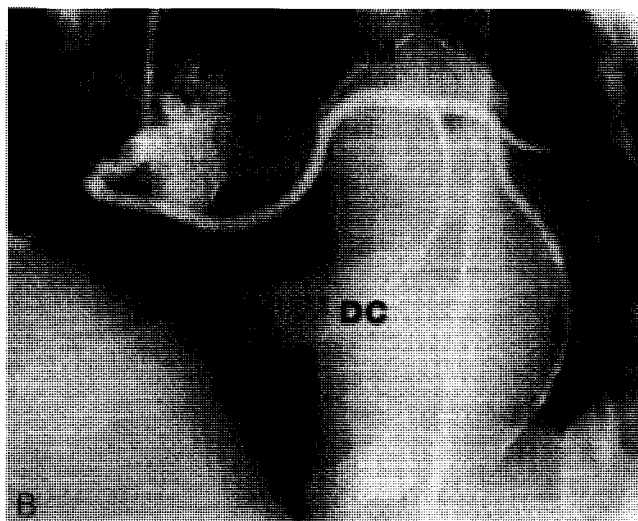
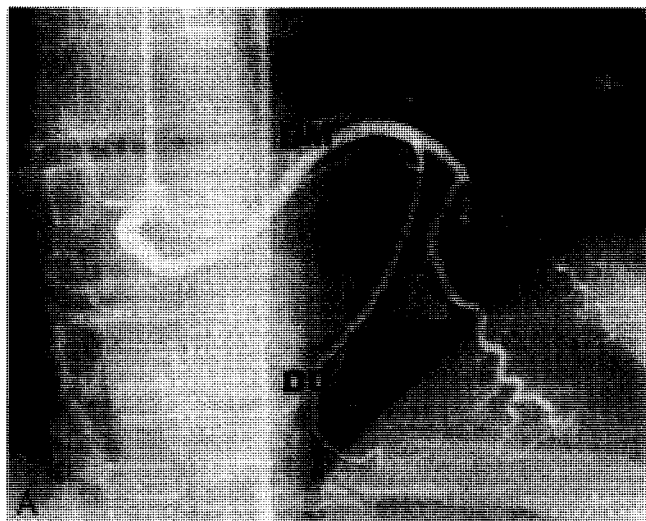


Figure CR4.17. Angiograms of the anomalous circumflex artery in the posteroanterior (A) and left anterior oblique (B) projections. The artery follows the posterior aortic annulus as far as the origin of the first branch, the ramus intermedius (RM). Also visible is the distal circumflex (DCx) and codominant (circumflex-right) pattern. C. Angiogram of the LAD in the right anterior oblique projection. In cases of this type, there is no left main trunk proper. D. Schematic diagram of the coronary anomaly (coronal plane). RM = ramus intermedius; DCx = distal circumflex.

CASE REPORT 4.18

Anomalous Location of the Coronary Ostium in the Opposite Sinus: Circumflex Artery Arising From the Right Anterior Sinus and Following a Retroaortic Path

A 55-year-old woman, with a history of rheumatic heart disease and mitral valve replacement, presented with a significant paravalvular leak, as diagnosed by transesophageal echocardiography. Preoperative cardiac catheterization (Fig. CR4.18, A–C)

showed that the circumflex artery arose from the right coronary sinus and confirmed that significant mitral insufficiency was present. The patient underwent successful repeat mitral valve replacement. ■

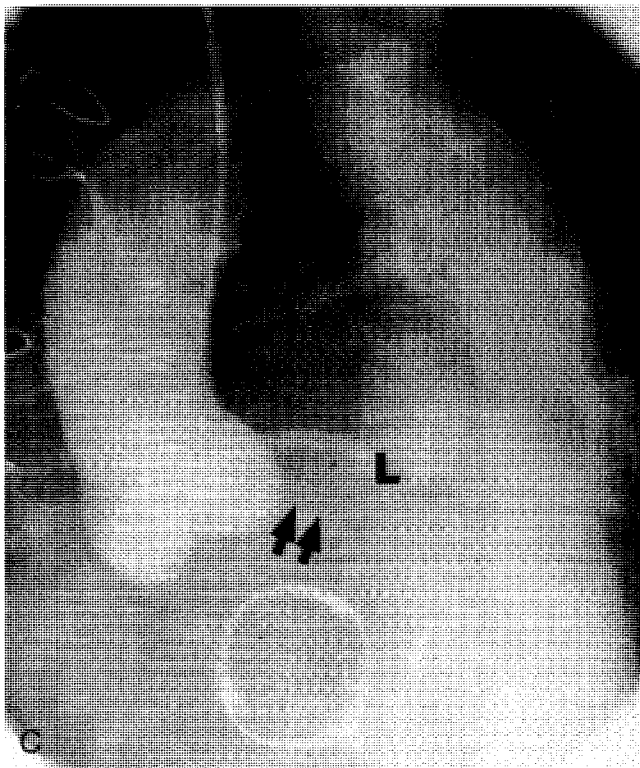
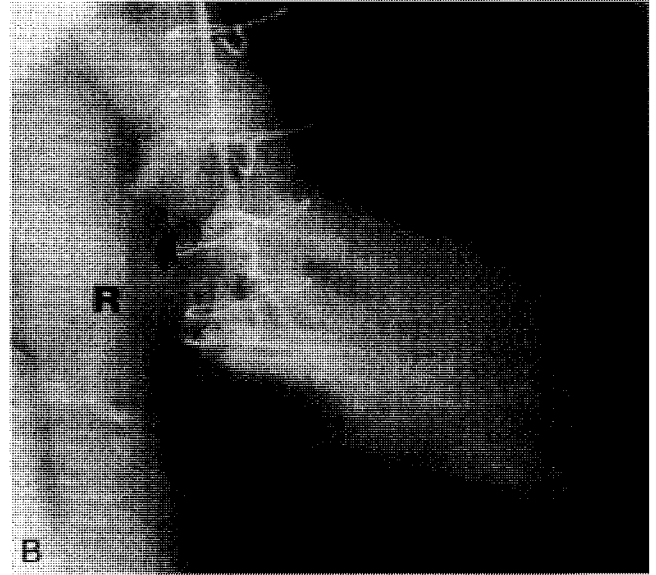
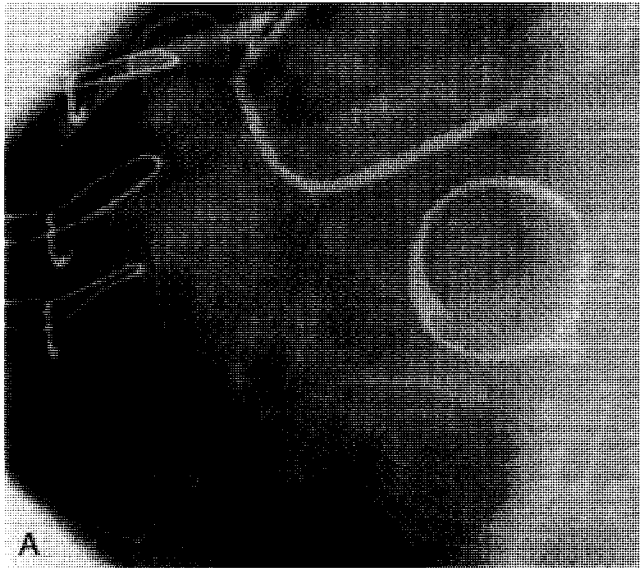


Figure CR4.18. A. Angiogram of the RCA and circumflex artery, in the left anterior oblique projection, showing adjoining ostia in the right anterior sinus. The circumflex artery is relatively small. B. Left ventriculogram, in the right anterior oblique projection, showing the relationship between the aortic and mitral valves; the anomalous circumflex artery exhibits a “nipple,” or “dot,” sign (arrow). C. Aortogram, in the left anterior oblique projection, showing normal origination of the LAD from the left sinus. The anomalous circumflex artery (arrowheads) is barely visible at the bottom of the left sinus. L = LCA.

CASE REPORT 4.19**Anomalous Location of the Coronary Ostium in the Opposite Sinus: Circumflex Artery Arising From the Right Anterior Sinus (Right Mixed Trunk) and Following a Retroaortic Path**

A 68-year-old woman with a history of hypertension, cigarette smoking, and hyperlipidemia was admitted for the evaluation of frequent severe chest pain. On cardiac catheterization, the small LAD was the only vessel seen to originate from the left sinus

(Fig. CR4.19, A–D). The dominant RCA arose jointly with the circumflex artery, which followed a retroaortic path. Mild prolapse of the mitral valve was noted, but no coronary obstructive disease was present. Medical treatment was recommended. ■

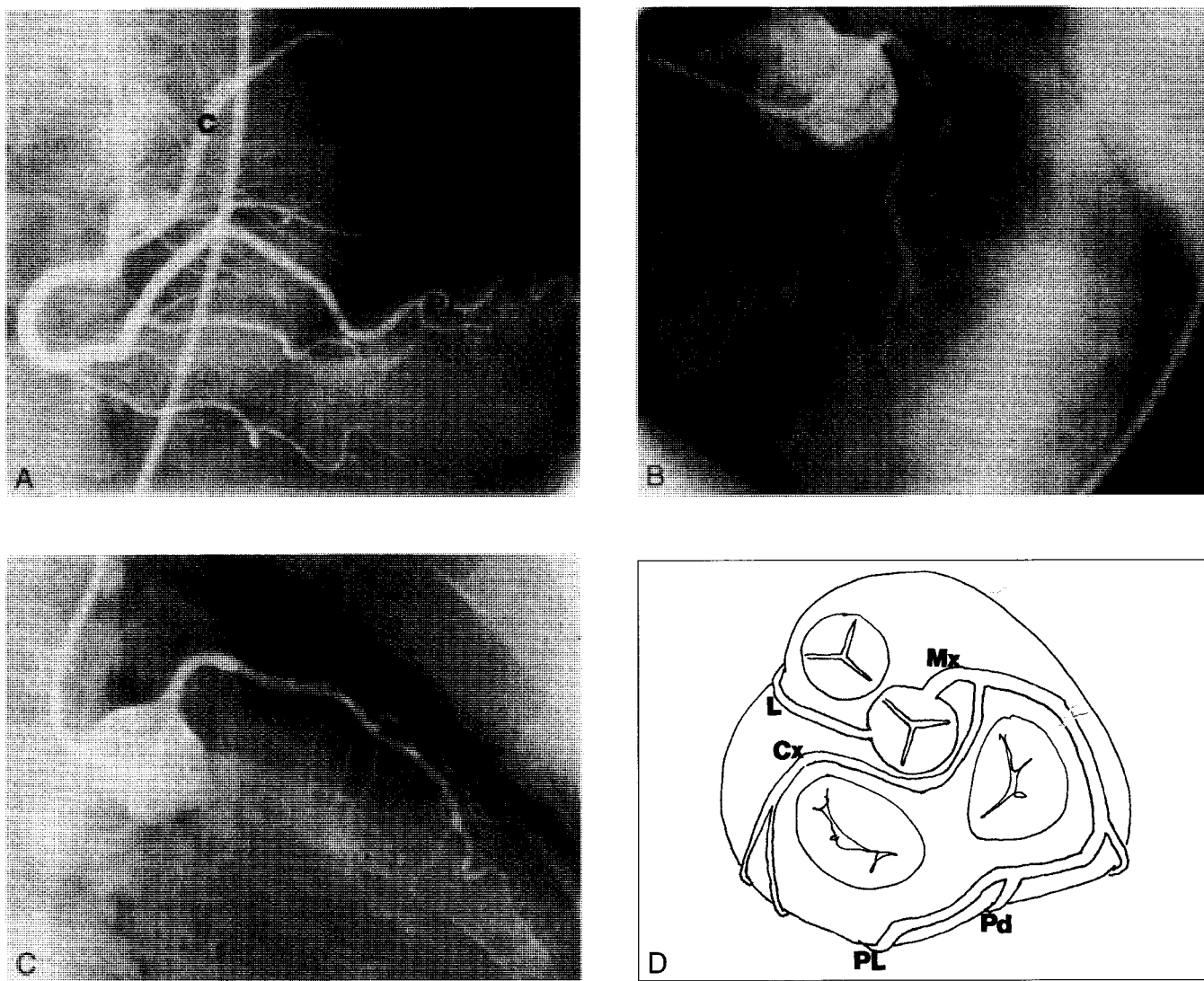


Figure CR4.19. A. Angiogram of the RCA in the posteroanterior projection, showing anomalous origination of the circumflex (Cx) artery from the proximal RCA. The distal RCA provides a large posterolateral branch (PL) that partially nourishes territory normally served by the circumflex artery. The circumflex artery itself is rather small. B and C. Left coronary angiograms in the left (B) and right (C) anterior oblique projections, showing that only the small LAD arises from the left sinus. D. Schematic diagram of the coronary anomaly (coronal plane). Cx = circumflex artery; L = LAD; Mx = mixed proximal trunk; Pd = posterior descending artery; PL = posterolateral branch.

CASE REPORT 4.20**Anomalous Location of the Coronary Ostium in the Opposite Sinus: Circumflex Artery Arising From the Right Anterior Sinus (Right Mixed Trunk) and Following a Retroaortic Path**

A 51-year-old man with a history of hyperlipidemia and angina was admitted because of worsening exertional angina. The patient had had a myocardial infarction 15 years earlier. Cardiac catheterization showed significant disease in all three major coro-

nary arteries (not illustrated). The circumflex artery originated from a right mixed trunk and coursed behind the aorta (Fig. CR4.20). Surgical treatment of the coronary obstructive disease was successfully carried out. ■

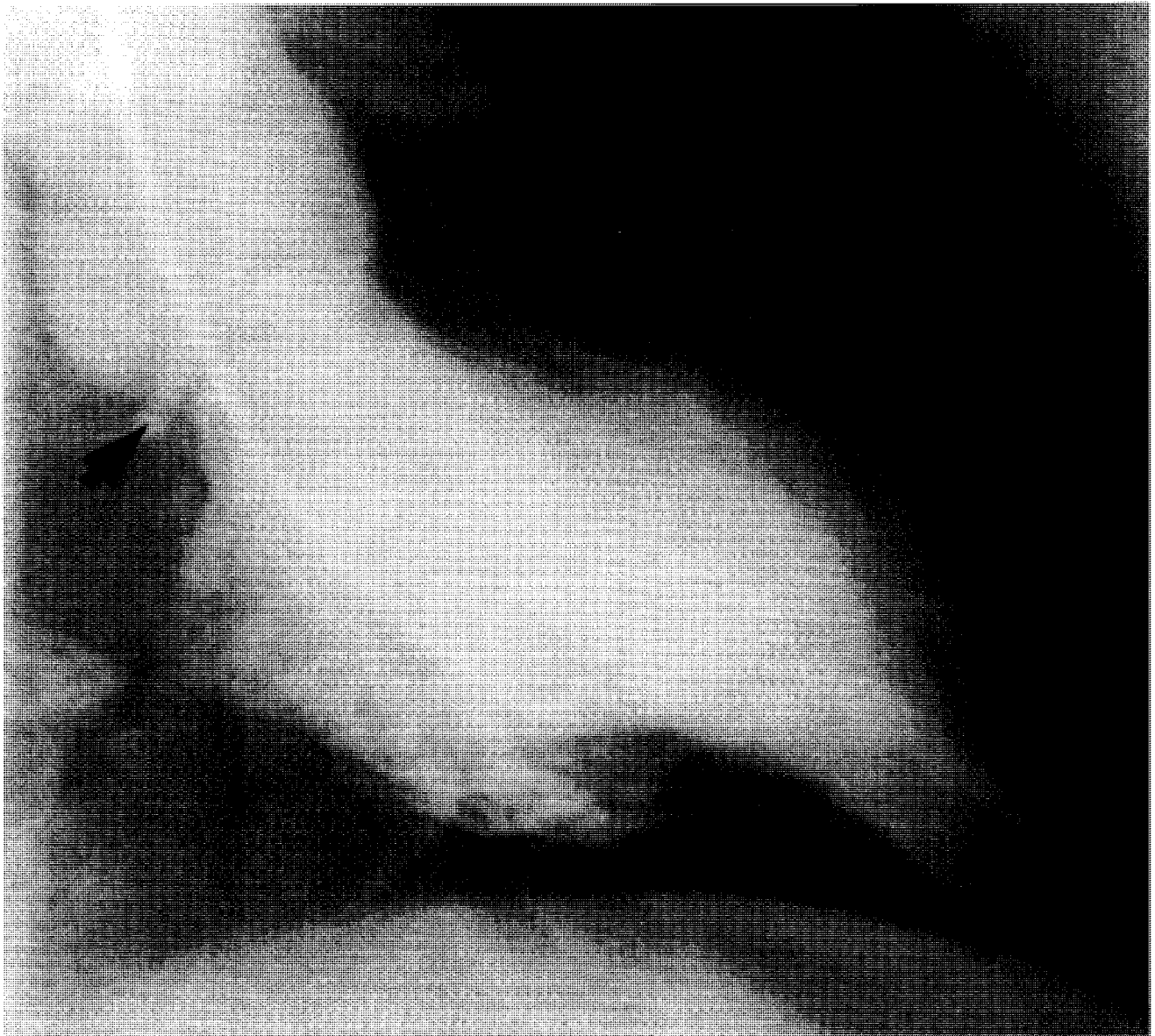


Figure CR4.20. Left ventriculogram in the right anterior oblique projection, showing the “nipple,” or “dot,” sign (arrow) that indicates a retroaortic circumflex artery. This angiographic sign is particularly consistent and pathognomonic, because the anomalous circumflex is seen longitudinally (with enhanced density of contrast material) in the right anterior oblique projection.

CASE REPORT 4.21**Anomalous Location of the Coronary Ostium in the Opposite Sinus: Circumflex Artery Arising From the Right Anterior Sinus (Right Mixed Trunk) and Following a Retroaortic Path**

A 38-year-old woman, who had had an “innocent” cardiac murmur since childhood, presented with a 1-year history of exertional dyspnea and mild cyanosis. Physical examination revealed a harsh 4/6 pansystolic murmur at the left sternal border. Cardiac catheterization showed a large ventricular septal defect and infundibular stenosis (anatomically, because the pulmonary valve was normal, the patient did not have tetralogy of Fallot; physiologically, however, she had a mild form of that anomaly). Coronary angiography revealed anomalous origination of the circum-

flex artery and the ramus medianus (RM), which arose with a common trunk from the right anterior sinus jointly with the RCA and followed a retroaortic path (Fig. CR4.21, A&B). The left anterior aortic sinus gave rise to only a small LAD artery (Fig. 4.21C) that did not reach the cardiac apex (dominant RCA with terminal branches wrapped around the apex). The patient underwent successful surgical correction of the congenital heart defect. ■

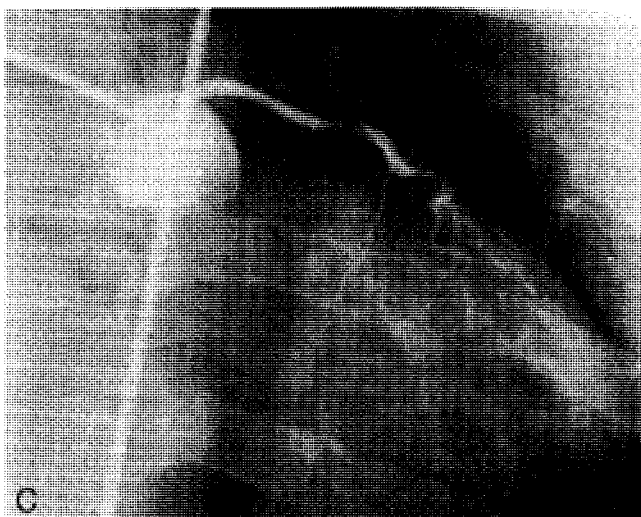
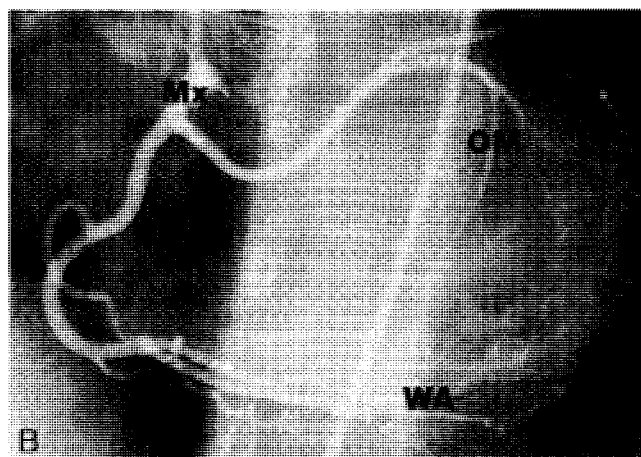
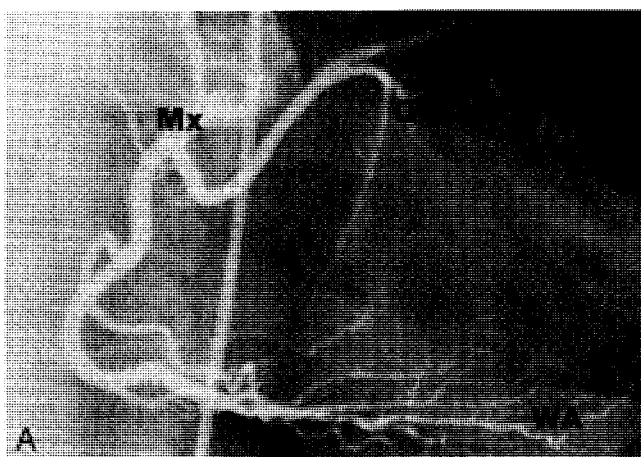


Figure CR4.21. Angiograms of the right anterior sinus artery in the posteroanterior (A) and left anterior oblique (B) projections. The initial common, mixed trunk (Mx) subdivided into a retroaortic circumflex/ramus artery (RM) and a dominant RCA. Note the unusual extent of the distal RCA, whose posterior descending branches wrap around the apex (WA). At the right cusp, the mixed trunk covers a larger territory than the normal left main trunk in the usual coronary pattern. In clinical practice, the term “left main equivalent” is used for this unusual pattern. OM = obtuse marginal branch. C. Solitary LAD arising from the left sinus.

CASE REPORT 4.22**Anomalous Location of the Coronary Ostium in the Opposite Sinus: Circumflex Artery Arising From the Right Anterior Sinus (Mixed Trunk) and Following a Retroaortic Path**

A 73-year-old man with new-onset typical exertional angina underwent an electrocardiographic treadmill test that was positive for coronary artery disease. His risk factors included hypertension, hyperlipidemia, and a family history of coronary artery disease. Coronary angiography revealed critical disease of an artery that originated from the left anterior aortic sinus. The artery did not supply the circumflex territory but only the LAD system (Fig. CR4.22, A and B). A large, trifurcated diagonal artery gave

rise to the ramus medianus. The right anterior aortic sinus had a single coronary ostium, which produced both a dominant RCA and an anomalous small circumflex artery that followed a retroaortic path (mixed initial trunk) (Fig. CR4.22, C and D). The circumflex artery had critical lesions in its proximal and mid portions. The patient underwent successful aortocoronary bypass of the LAD and diagonal arteries, but the circumflex artery was too small for a bypass graft. ►

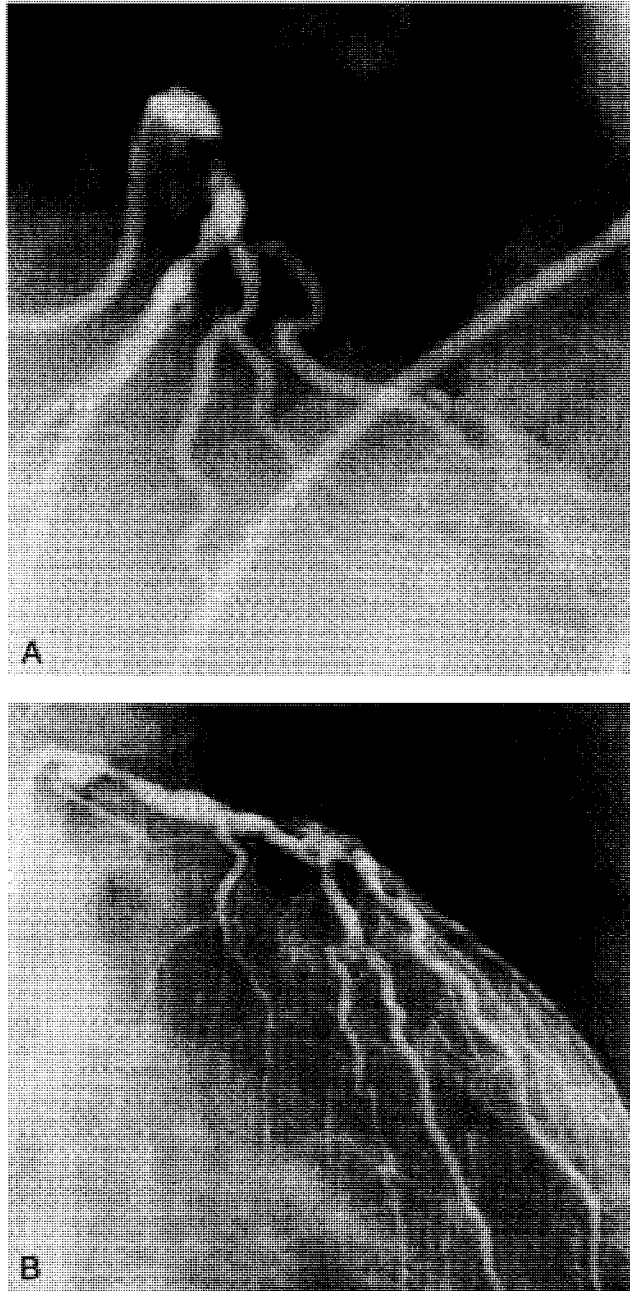


Figure CR4.22. See legend on next page

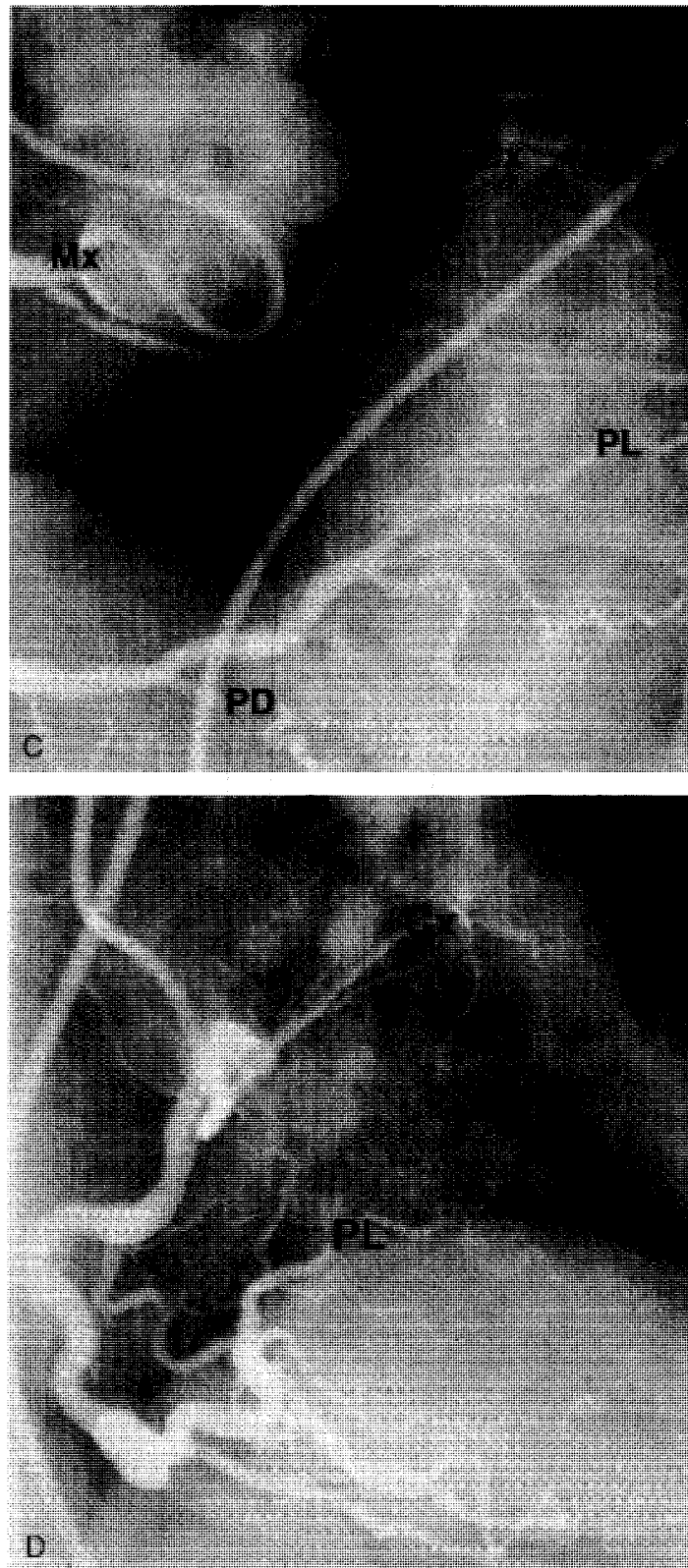


Figure CR4.22. Angiograms of the LAD in the left (A) and right (B) anterior oblique projections. Angiograms of the right coronary sinus, in the cranial left (C) and right (D) anterior oblique projections, showing a mixed trunk that arises from the right sinus. The posterolateral (PL) branch of the RCA supplies a larger territory around the obtuse marginal artery than does the circumflex artery (Cx) proper, which may be considered split. Mx = mixed proximal trunk; PD = posterior descending artery.

CASE REPORT 4.23

Anomalous Location of the Coronary Ostium: RCA Arising From the Left Anterior Sinus and Following a Retroaortic Path ("Single LCA")

A 56-year-old woman presented with recent-onset typical angina and exertional dyspnea 4 years after having an unconfirmed acute myocardial infarction. Electrocardiographic treadmill testing was negative for coronary artery disease. Coronary angiography revealed no significant coronary obstructive disease. Left ventricular angiography showed a normal volume and normal wall motion (Fig. CR4.23, A). The RCA arose from the left ante-

rior sinus, by way of a mixed trunk that was shared with the left coronary system (single coronary artery arising from the left anterior sinus) (Fig. CR4.23, B–E). The RCA followed a retroaortic path (Fig. CR4.23, A, *double arrows*). No coronary artery was observed in the right anterior sinus. Continued medical treatment was recommended. ►

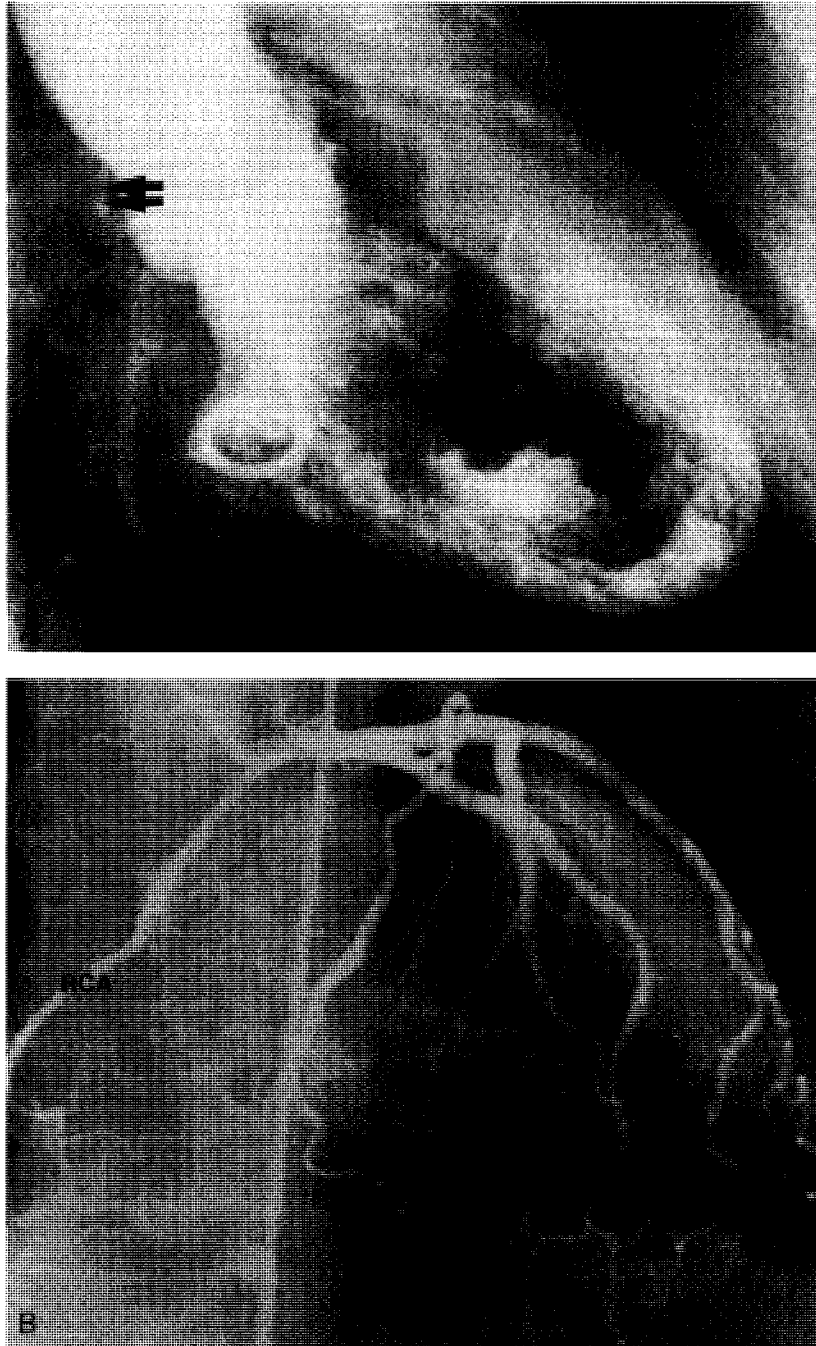


Figure CR4.23. See legend on next page

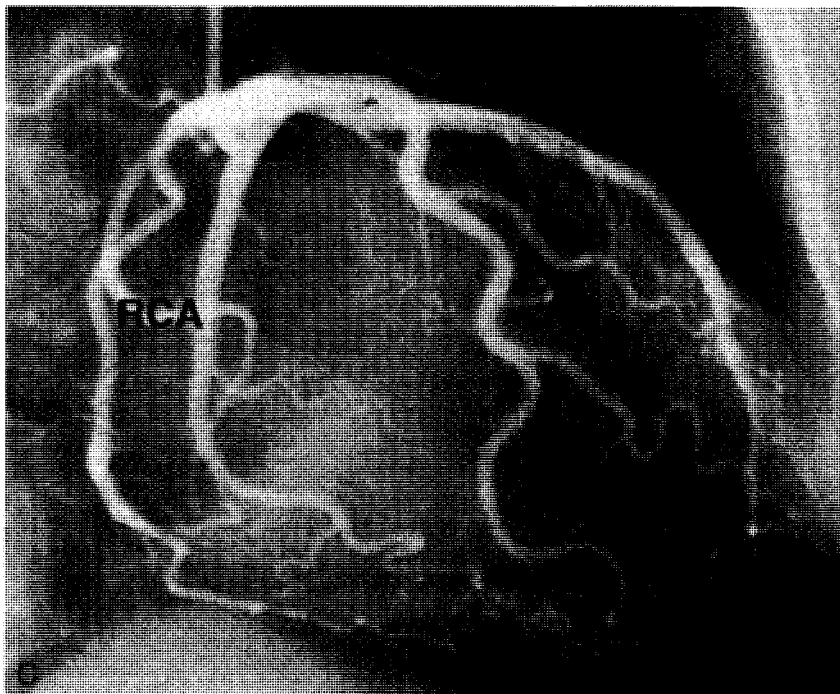
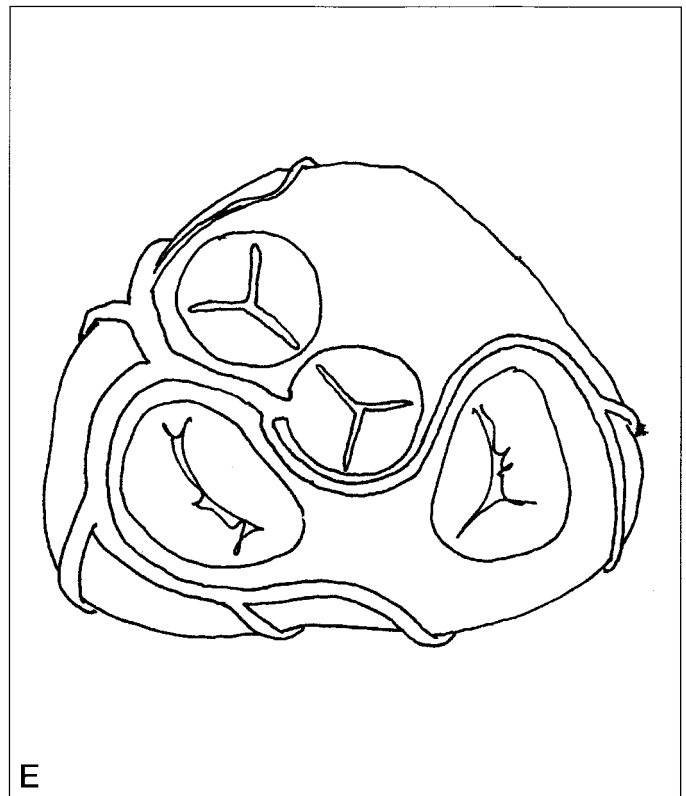
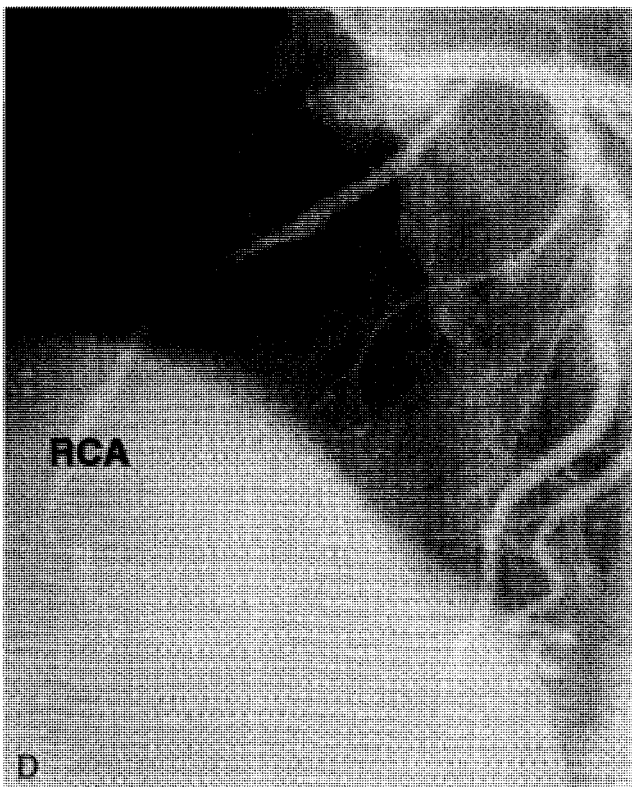


Figure CR4.23. A. Left ventriculogram in the right anterior oblique projection. The RCA (arrows) courses behind the aortic root. Coronary angiograms in the posteroanterior (B), right anterior oblique (C), and left anterior oblique (D) projections show that the circumflex artery is dominant and the RCA relatively small. E. Schematic diagram of the coronary anomaly (coronal plane).



CASE REPORT 4.24

RCA Arising From the Left Anterior Sinus and Coursing Anomally “Between the Aorta and Pulmonary Artery” (Preaortic Path)

A 42-year-old man with hypertension and a family history of heart disease was admitted because of an acute anteroseptal infarction. During the preceding few weeks, the patient had had effort-related angina. Echocardiography revealed an ejection fraction of 45%, with akinesia of the mid and distal portions of the septum. Coronary angiography showed a subtotal stenosis of the LAD. The RCA, which was totally occluded, shared a common mixed trunk with the LCA, arising from the left anterior sinus

and coursing between the aorta and pulmonary artery (Fig. CR4.24, A–E). The patient underwent successful aortocoronary bypass surgery.

Comment: In this case, a coronary anomaly that had the potential for causing sudden death was discovered during assessment of acquired atherosclerotic disease at a site remote from the anomalous path. ►

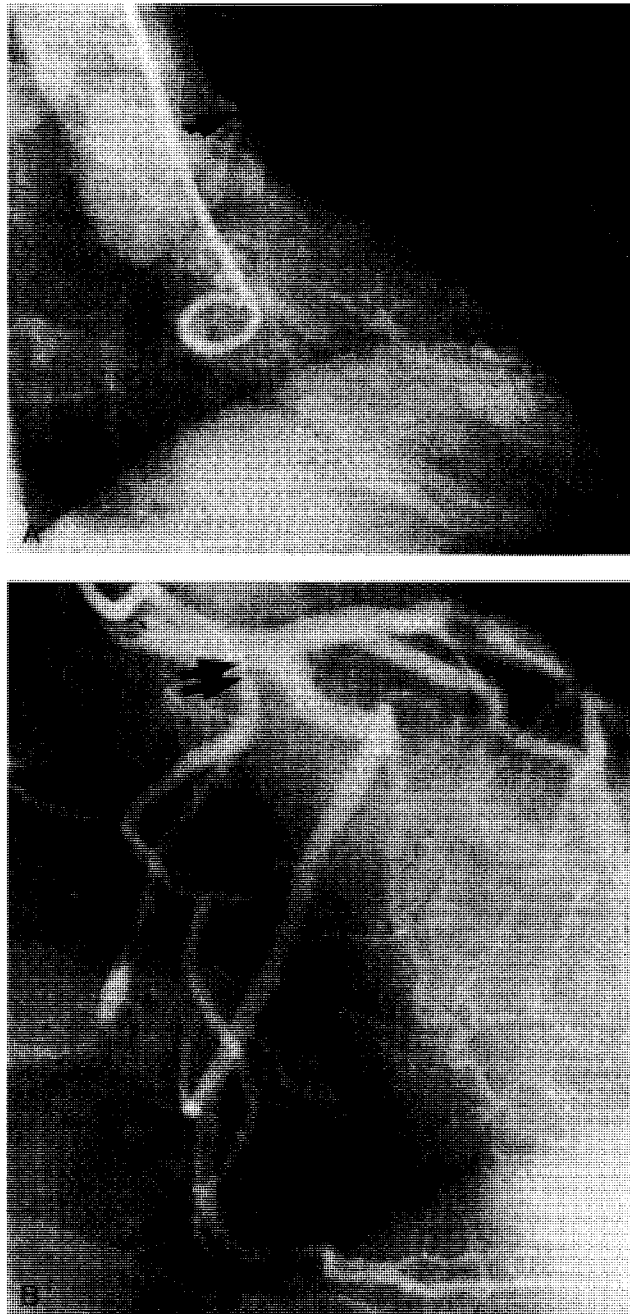


Figure CR4.24. See legend on next page

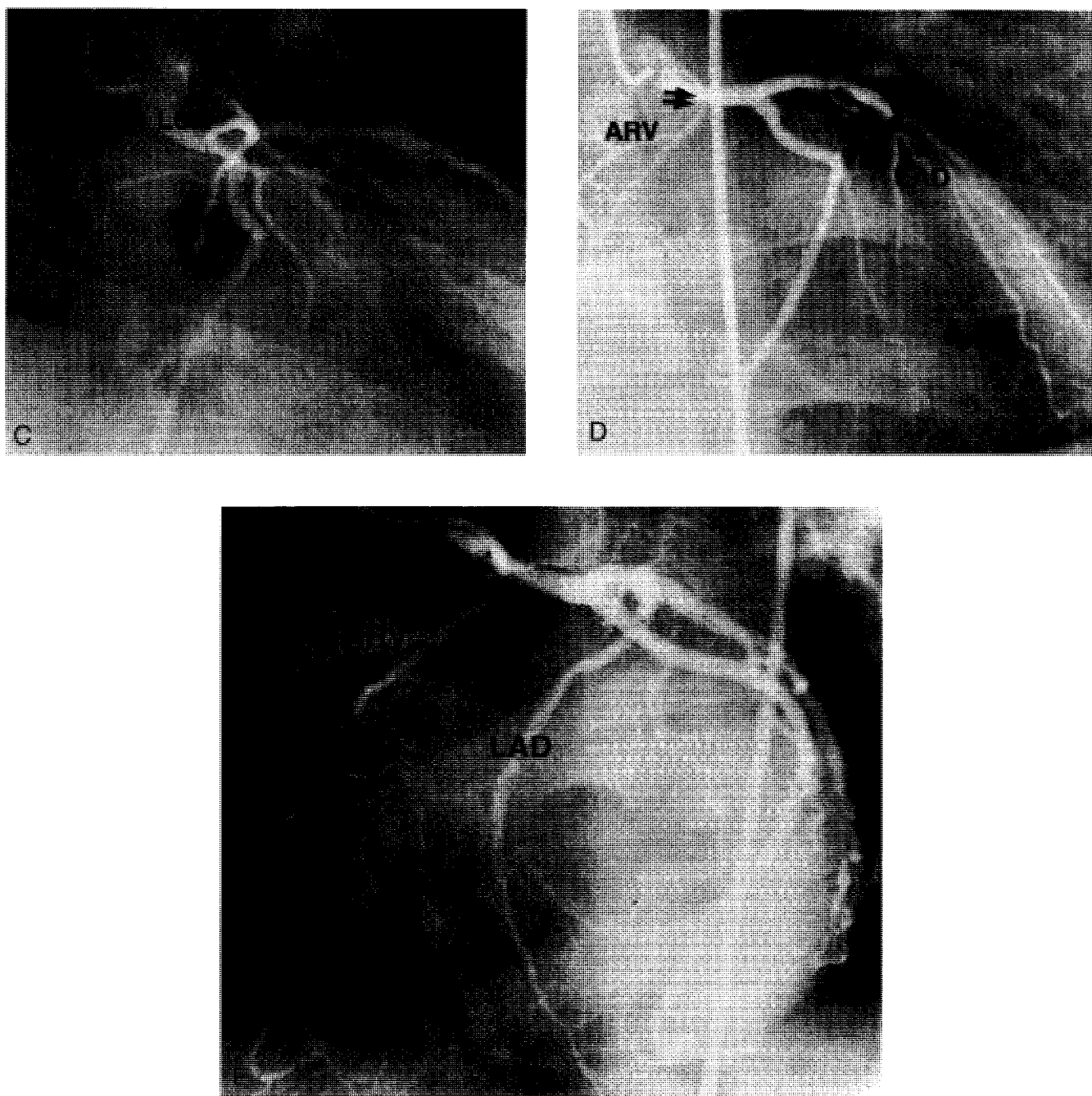


Figure CR4.24. **A.** Left ventriculogram in the right anterior oblique projection, showing inferoapical akinesia and suggesting that the RCA has an anomalous path anterior to the aortic root (arrow). Angiograms of the left coronary trunk in the straight (**B**) and caudal (**C**) right anterior oblique projections show early splitting of the left mixed trunk. A long, eccentric stenotic lesion appears to lie against the aortic wall (view **B**, arrows) in the concavity of the RCA. **D** and **E.** Angiograms of the left coronary ostium in the posteroanterior (**D**) and left anterior oblique (**E**) projections. In the RCA, an occlusion is present, distal to the initial eccentric lesion (view **D**, arrows) and the origin of the large anterior right ventricular branch (ARV). LAD = left anterior descending artery.

CASE REPORT 4.25

Anomalous Location of the Coronary Ostium in the Opposite Sinus: RCA Arising From the Left Sinus and Following a Preaortic Path

A 48-year-old man with hypertension and exertional angina underwent thallium stress testing, which revealed ischemia of the inferior left ventricular wall. Cardiac catheterization showed multiple nonobstructive plaques in the LCA (Fig. CR4.25, A). The

RCA arose independently from the left coronary sinus, coursed between the aorta and the pulmonary artery, and had a 60% proximal eccentric stenotic lesion (Fig. CR4.25, B and C). Surgical treatment was recommended. ■

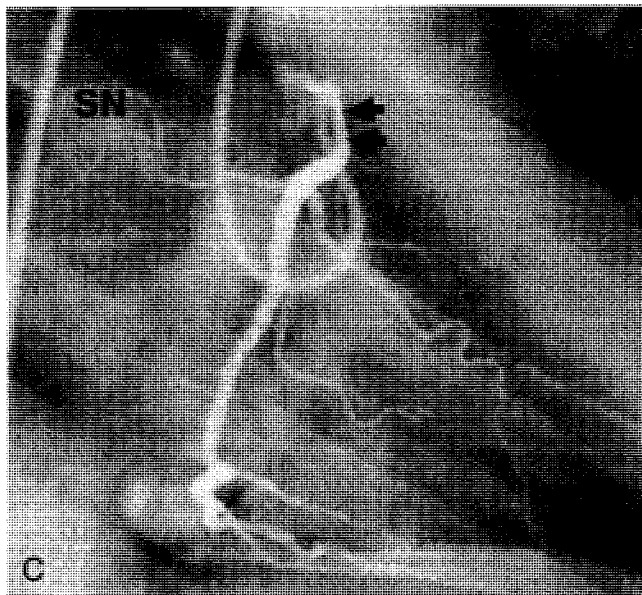
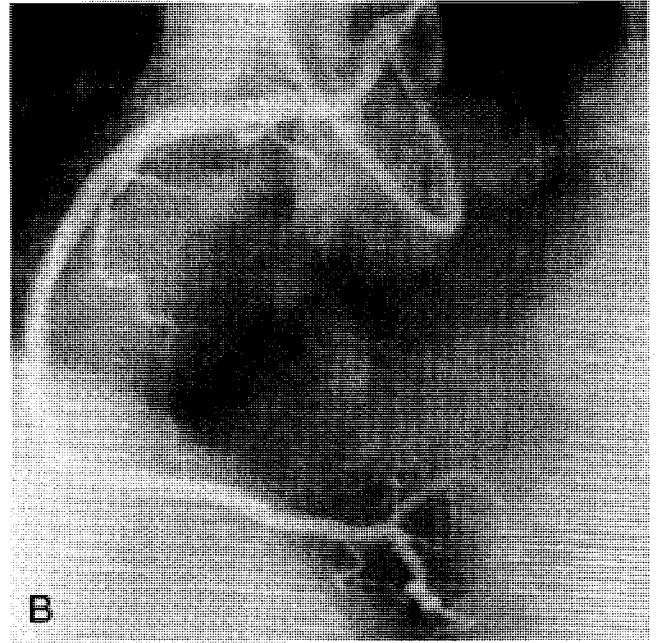
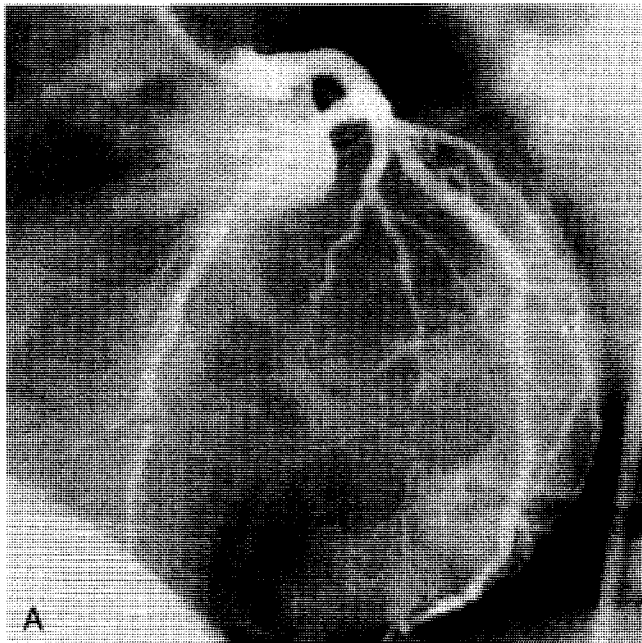


Figure CR4.25. A. Normal angiogram of the LCA in the left anterior oblique projection. Angiograms of the RCA in the left (B) and right (C) anterior oblique positions, showing the artery's ectopic origination and course. The ostium is located high above the left coronary sinus and features a proximal, tangential tract with an eccentric, stenotic lesion that is best visualized in the right anterior oblique view (C, arrows). SN = sinus node artery.

CASE REPORT 4.26**Anomalous Location of the Coronary Ostium in the Opposite Sinus: RCA Arising From the Left Sinus (Left Mixed Trunk) and Following a Preaortic Path ("Single LCA")**

A 77-year-old hypertensive male smoker presented with a history of dyspnea, angina, and near syncope. Echocardiography revealed a critical aortic stenosis. Cardiac catheterization showed no significant coronary obstructive lesions, but the RCA arose anomalously from a left mixed trunk and followed a preaortic path (Fig. CR4.26, A–D). The patient underwent successful aortic valve replacement and prophylactic aortocoronary venous by-

pass grafting of the RCA. The anatomopathology of the aortic valve suggested a congenital bicuspid anomaly rather than rheumatic valve disease. This case is another example of "single LCA." The indication for a "prophylactic" RCA bypass is not well established, but such a surgical procedure is clearly justified in a patient who requires cardiac surgery for other reasons (in this case, aortic valve replacement). ■

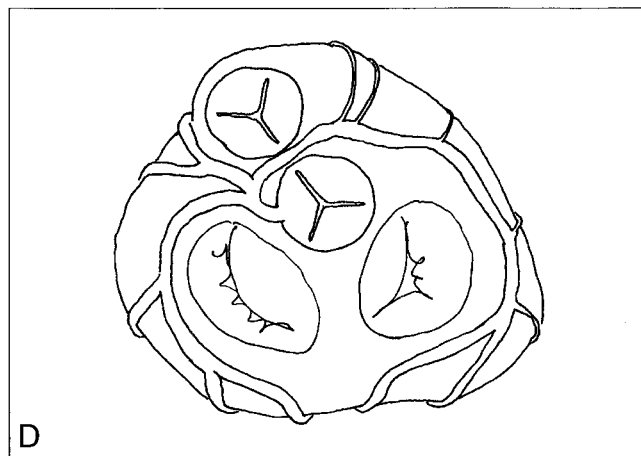
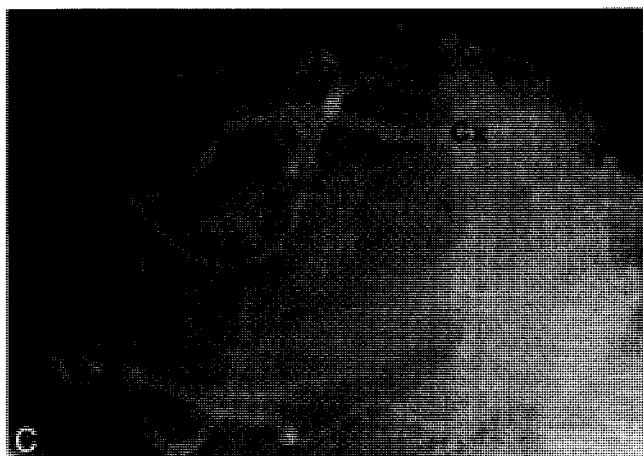
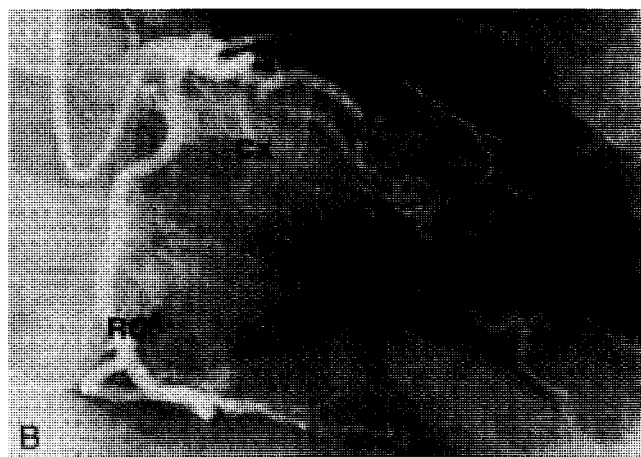
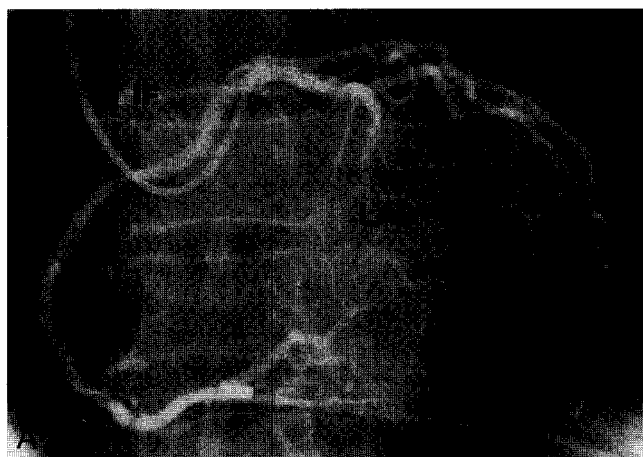Figure CR4.26. Angiograms of the LCA in the following projections: posteroanterior (A), right anterior oblique (B), and left anterior oblique with a slight caudal tilt (C). The dominant RCA takes off from the proximal common (mixed) trunk at a 90° angle and immediately pursues a normal course in the right atrioventricular groove, as shown by the origination of the infundibular branches (IF). (D) Schematic diagram of the coronary anomaly (coronal plane). Cx = circumflex artery; L = LAD; R = RCA.

CASE REPORT 4.27

LAD Arising From the Right Anterior Sinus and Following an Intraseptal Path (Split LAD)

A 64-year-old man with early-stage cutaneous T-cell lymphoma was admitted for unstable angina. The patient had multiple risk factors for coronary artery disease and had previously undergone repair of an abdominal aortic aneurysm. Coronary angiography showed proximal occlusion of the RCA and circumflex artery, as well as severe stenosis of the left main vessel (Fig. CR4.27, A–E). The LAD arose from the right anterior sinus, next to the stump of the RCA, and followed an intraseptal path, supplying the mid and distal portions of the anterior left ventricular wall.

The LAD also supplied collateral circulation to the posterior descending artery of the RCA and obtuse marginal branches of the circumflex. The patient underwent aortocoronary bypass grafting of the RCA, LAD, and diagonal and obtuse marginal branches. This case is another example of a split LAD. It could also be termed “anomalous origination of the LAD from a septal branch,” since the proximal vessel that originates from the right sinus predominantly has the features of a septal branch (with respect to its course and the majority of its branches). ►

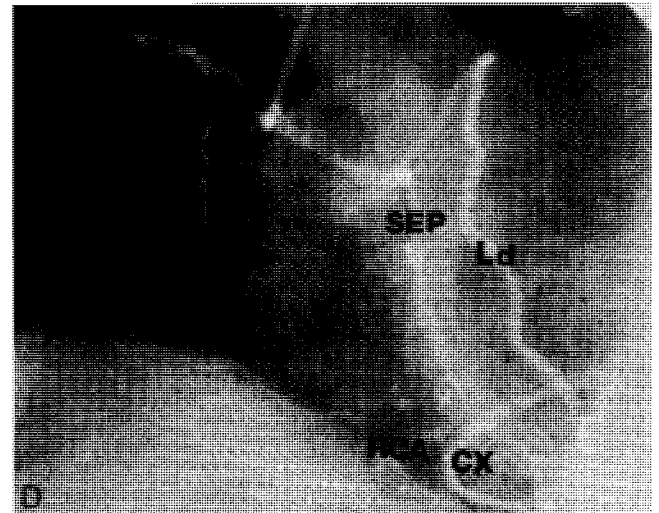
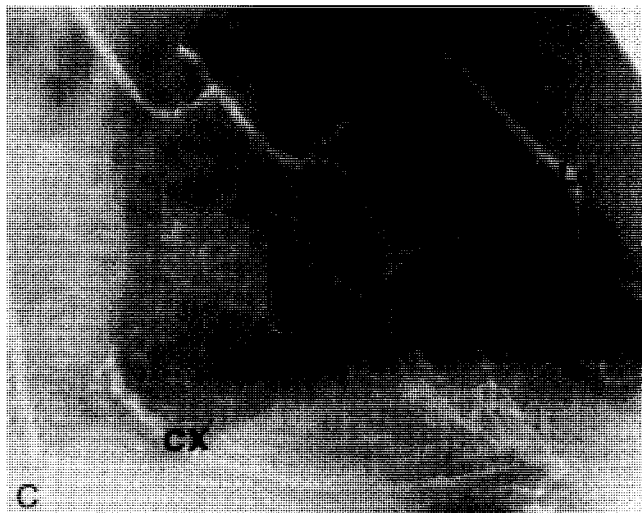
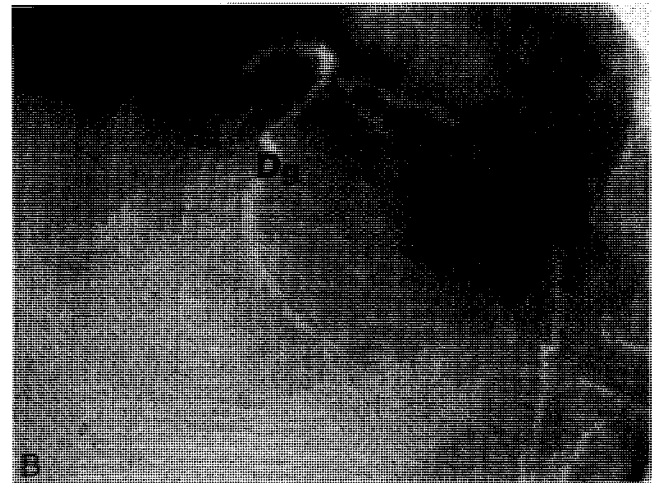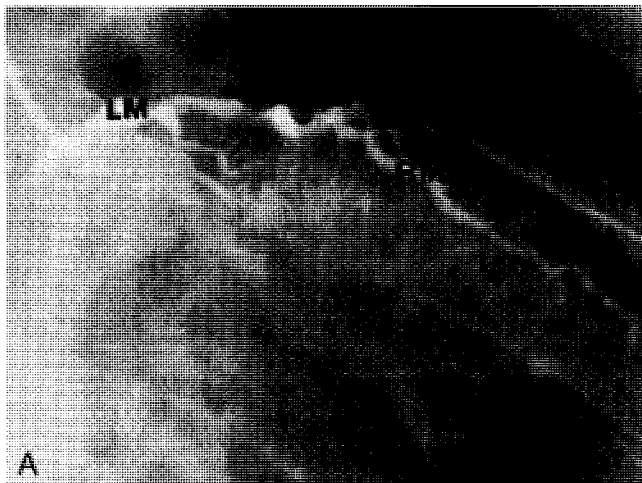


Figure CR4.27. Angiograms of the LCA in the right (A) and left (B) anterior oblique projections. The LAD is not totally absent from the left side: the proximal anterior trunk (LM) soon subdivides into a first septal (1st) and a large diagonal branch (Dg) and a ramus (RM). The circumflex artery is totally occluded but shows a dominant pattern when it fills via collateral vessels from the ectopic LAD. Angiograms of the right anterior sinus, in the right (C) and left (D) anterior oblique projections, reveal a totally occluded proximal RCA, which arises from a single niche shared with the ectopic LAD. The LAD courses lower than is usual in similar anomalies (see Case Report 4.28): it descends into the left ventricular septum and gives rise to a large septal branch (SEP) (which supplies most of the septum) before resurfacing in the proximal anterior interventricular groove. Cx = circumflex artery. continued

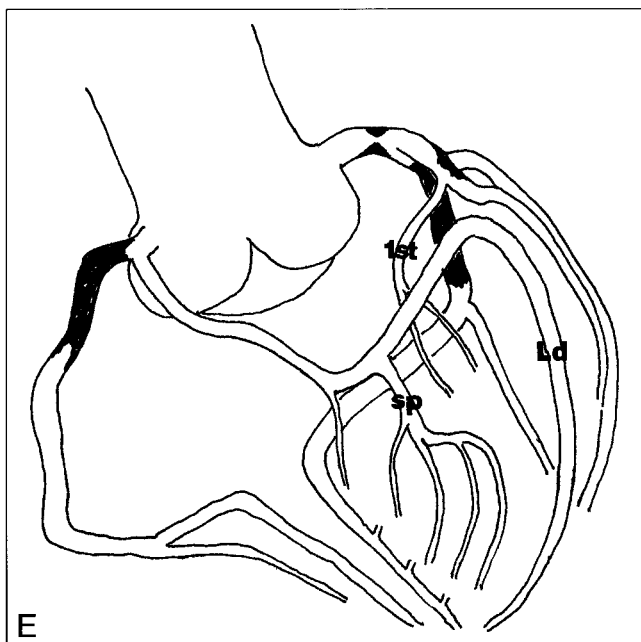


Figure CR4.27. (continued) **E.** Schematic diagram of the coronary anomaly (frontal plane); 1st = first septal branch; Ld = left anterior descending; sp = septal.

CASE REPORT 4.28**Anomalous Location of the Coronary Ostium in the Opposite Sinus: LCA Arising From the Right Anterior Sinus and Following an Intraseptal Path**

A 74-year-old man, with hypertension, hyperlipidemia, and a family history of coronary artery disease, presented with acute severe chest pain that occurred on mild exertion and was associated with diaphoresis. The patient's cardiac enzyme levels were elevated, suggesting a non-Q-wave acute myocardial infarction.

Cardiac catheterization showed a critical stenosis in the mid RCA and minimal plaques in the LCA, which arose from the right coronary sinus (Fig. CR4.28, A–D). Medical treatment was recommended. ■

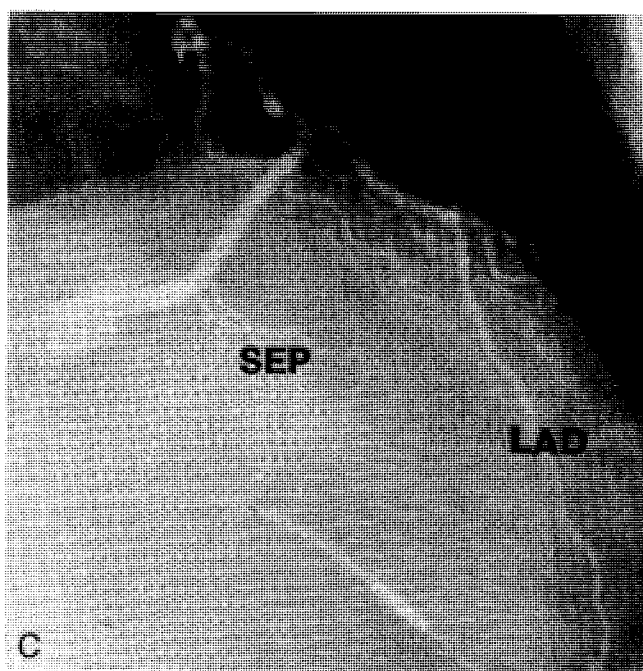
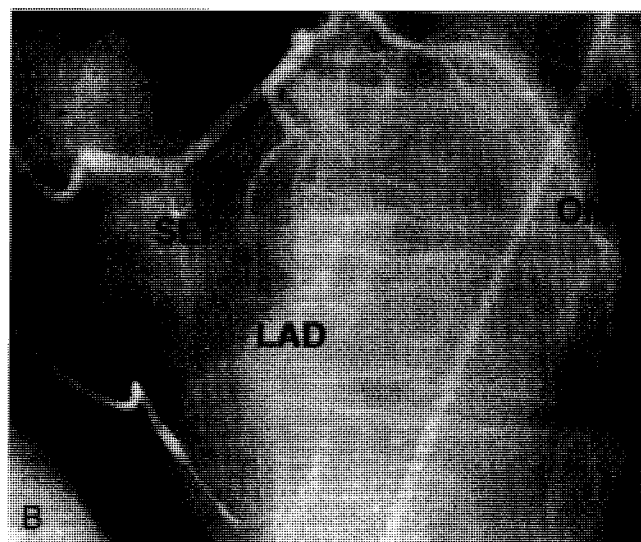
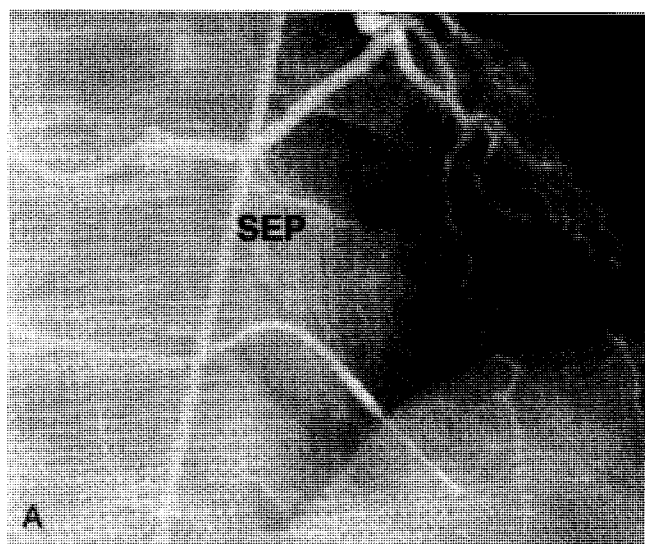


Figure CR4.28. Angiograms of the LCA in the posteroanterior (A), left anterior oblique (B), and cranial right anterior oblique (C) projections. The artery's ostium is located in the right anterior sinus, adjacent to the right coronary ostium. The left main trunk produces a large septal vessel (SEP) as its first ramification, soon after the left main trunk enters the ventricular septum, before terminating in the LAD and the circumflex/obtuse marginal (OM) artery.

CASE REPORT 4.29**LCA Arising From the Right Anterior Sinus and Following an Intraseptal Course**

A 59-year-old man had a history of mild dyspnea on exertion. Because an echocardiographic workup revealed left ventricular dysfunction, the patient underwent heart catheterization. Left ventricular angiography revealed a left ventricular ejection fraction of 30%, with a diffuse, even pattern of hypokinesia (Fig. CR4.29, A). Selective coronary angiography failed to show a coronary ostium in the left anterior sinus; this absence was confirmed by means of aortography (Fig. CR4.29, B). The LCA arose adjacent to the right coronary ostium, in the right anterior sinus (Fig. CR4.29, C–F). The left main trunk was initially considered to run “between the aorta and pulmonary artery,” but further analysis indicated an intraseptal course. No significant coronary obstructive lesions were seen. Medical treatment was continued; prophylactic bypass of the left coronary system was seriously considered but was not performed.

Comments: This case involved an intriguing association between a coronary anomaly and a severe left ventricular myopathy of unknown etiology. Whereas preaortic coursing of the LCA is known to be associated with left ventricular myopathy, intraseptal coursing of that artery does not seem to have such an association, although the subject remains open to investigation. A review of the angiographic literature suggests that the preaortic, intraseptal, and prepulmonic courses are best differentiated from each other in the right anterior oblique projection (Fig. CR4.29, F–G). The anomalous preaortic left main trunk (coursing between the aorta and the pulmonary artery) assumes a slightly superoposterior path and reaches the left main stem usual site before separating into the circumflex artery and the LAD (as shown in the literature⁴³⁵). In our experience, most of the cases labeled as preaortic in clinical practice have actually turned out to be intraseptal on critical analysis. ►

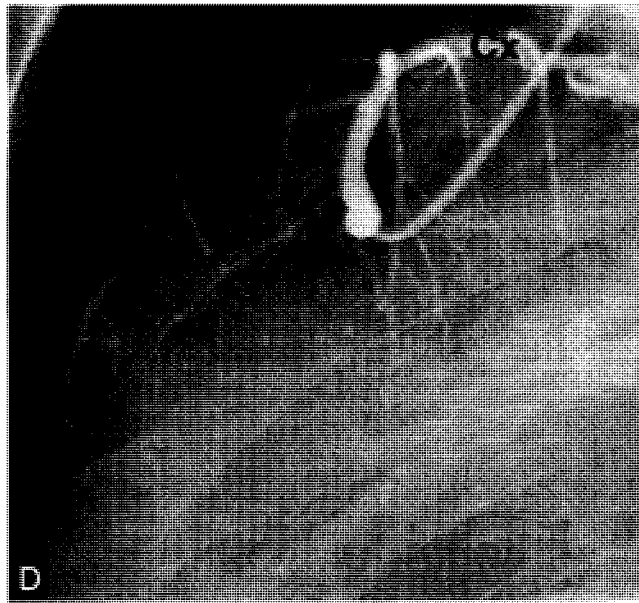
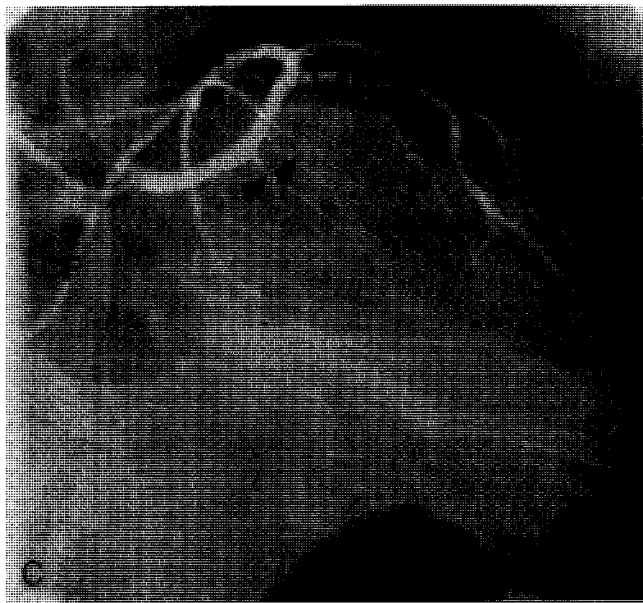
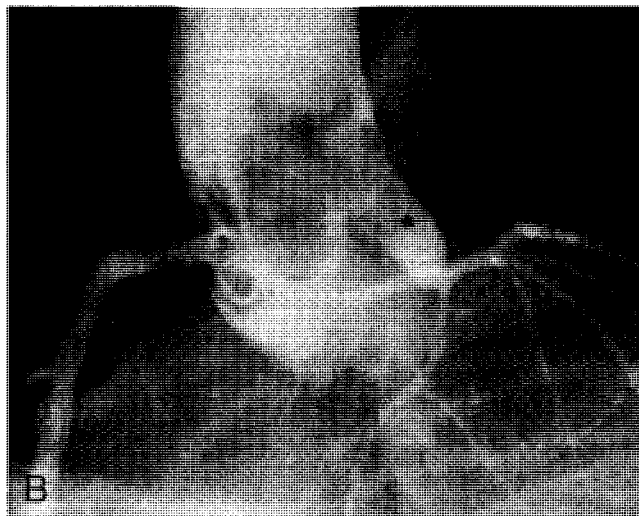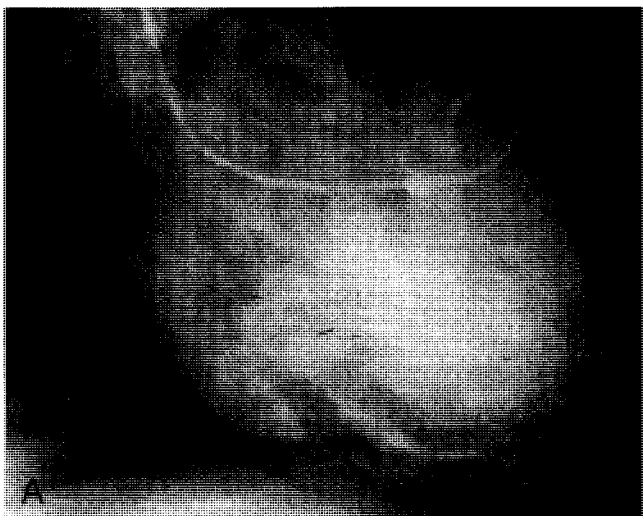


Figure CR4.29. See legend on next page

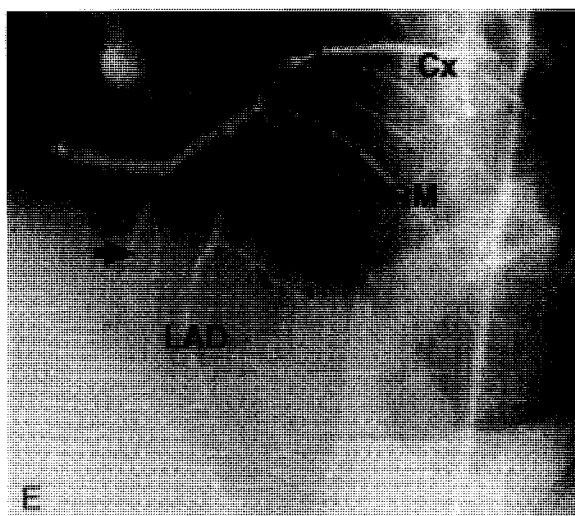
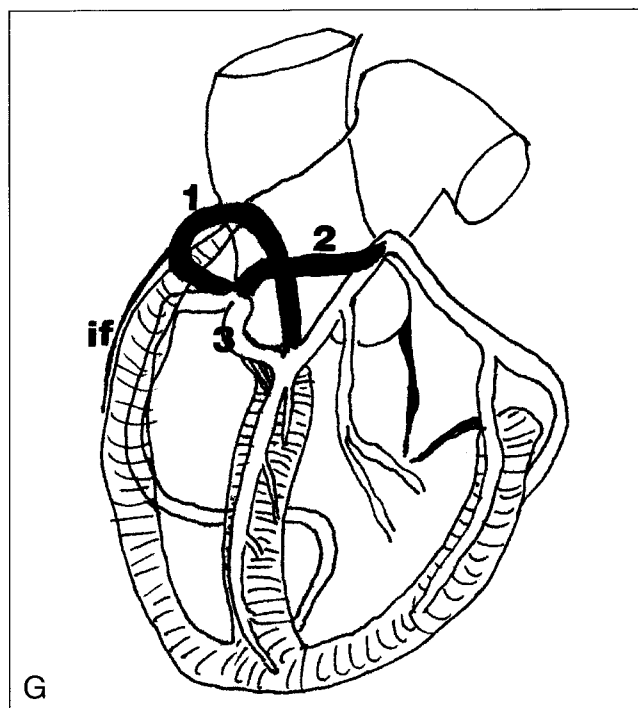
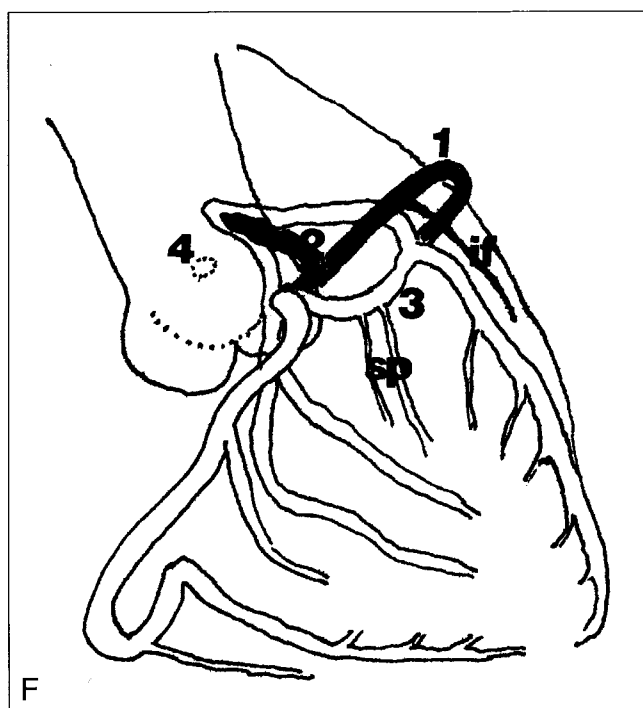


Figure CR4.29. **A.** Left ventricular angiogram in the right anterior oblique projection (systolic frame), showing diffuse, severe hypokinesia and cavitory dilation. **B.** Aortogram of the ascending aorta in the left anterior oblique projection, showing the absence of a normally located left coronary ostium at the left anterior sinus (asterisk). This sinus appears to be somewhat smaller than the other two sinuses. The anomalous origin of the LCA is clearly demonstrated, suggesting an intraseptal path (which is lower than the aortic root), as discussed in the Comments Section. **C–E.** Selective angiograms of the LCA in the right anterior oblique (**C**), lateral (**D**), and caudal left anterior oblique (**E**) projections, showing the LCA branches (arrowheads = septal branches; RM = ramus; Cx = circumflex artery). The left main trunk is considered to follow an intraseptal path, because it turns anteriorly and slightly inferiorly (view **D**), gives off septal branches (arrows), and reaches the proximal LAD before the circumflex artery (Cf). **F** and **G.** Diagrams of differential angiographic features of the left main coronary artery in the right (**F**) and left (**G**) anterior oblique projections, showing the artery's three different "anterior" paths as it originates anomalously from the right sinus: 1, prepulmonic; 2, preaortic; 3, intraseptal, and 4, expected site of left coronary ostium. Only the preaortic course seems to be clearly associated with an unfavorable prognosis (see also Types of Pathophysiologic Mechanisms and Clinical Implications, pages 63–69). if = infundibular branch; sp = septal branches.



CASE REPORT 4.30**Anomalous Location of the Coronary Ostium in the Opposite Sinus: LAD Arising From the Right Anterior Sinus and Following an Intraseptal Path**

A 49-year-old woman with diabetes mellitus and a history of angina had an acute inferior myocardial infarction that was treated with thrombolytic agents. Cardiac catheterization revealed occlusion of the proximal RCA, with inferior akinesia and a mildly decreased ejection fraction. The LAD originated from the right coronary sinus and followed an intraseptal path. The patient re-

fused to undergo coronary artery bypass surgery. Interestingly, a follow-up examination 2 years later showed that her coronary disease had progressed to involve the proximal circumflex, ramus intermedius, and LAD (at the ostium). The patient later succumbed to sudden death. ►

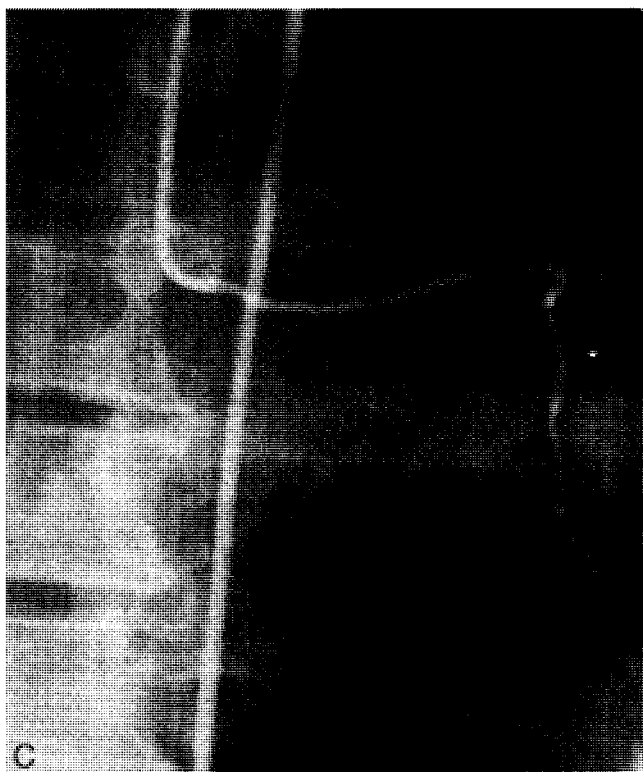
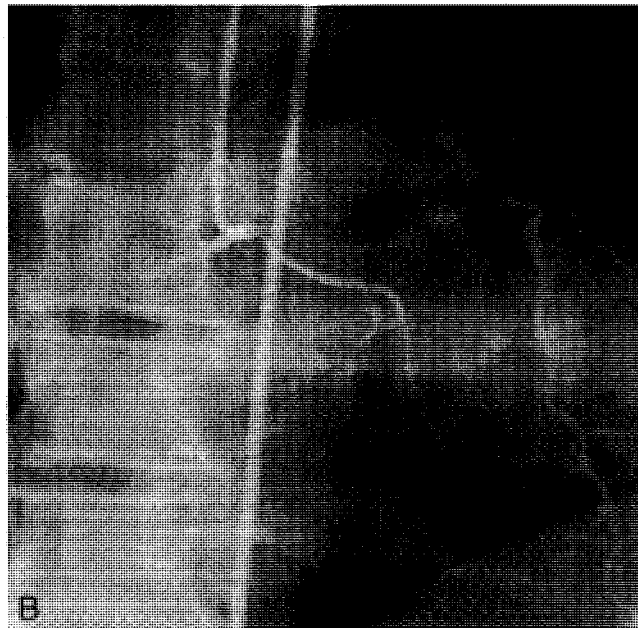
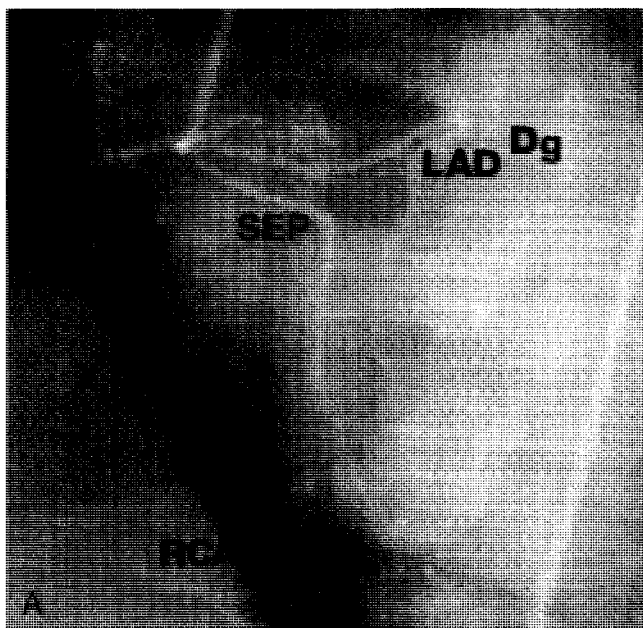


Figure CR4.30. Angiograms of the RCA in the left anterior oblique (A) and posteroanterior (B,C) projections. (continued)

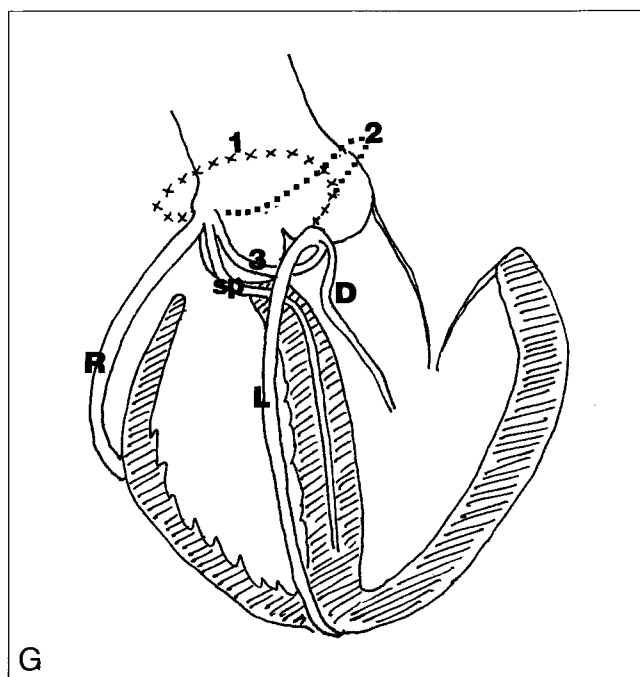
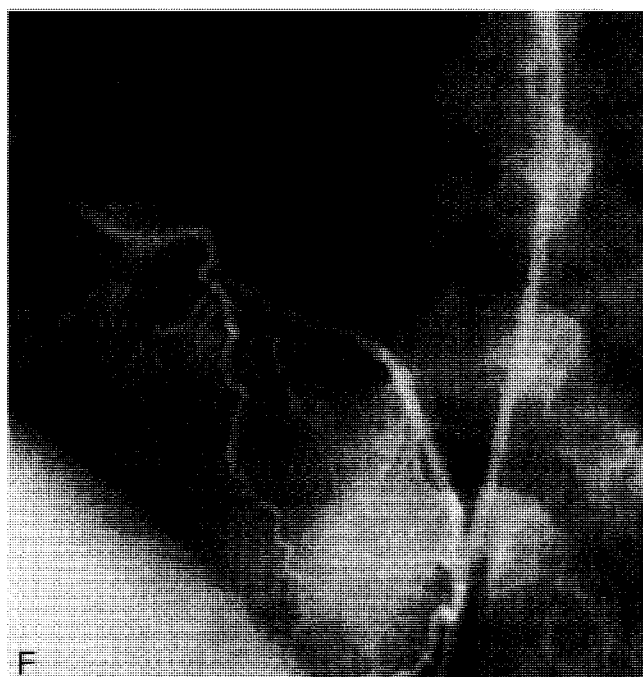
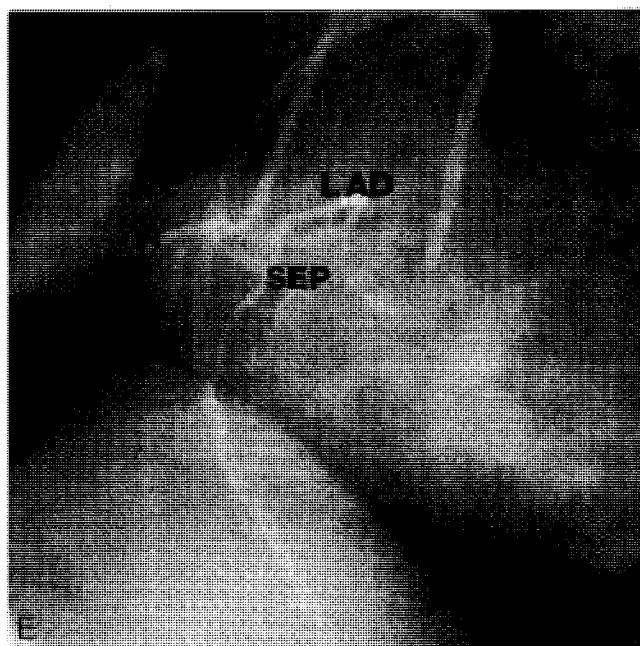
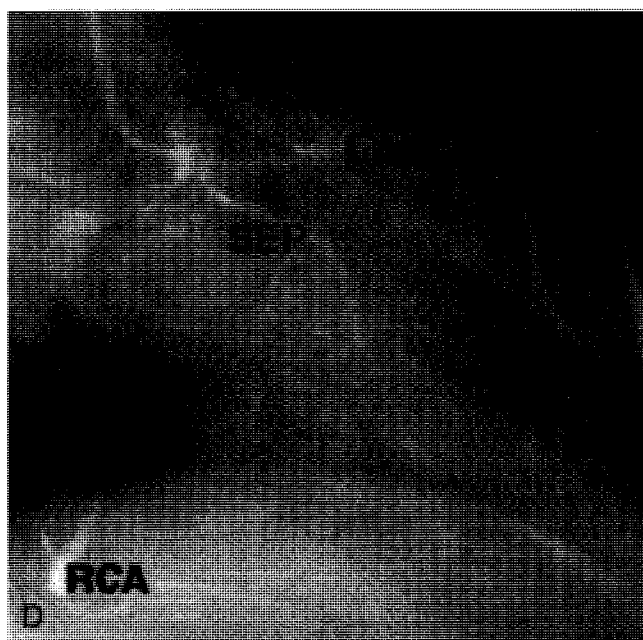


Figure CR4.30. (Continued) D,E. Angiograms of the RCA in the right anterior oblique (D), and lateral (E) projections. The short, mixed trunk arising from the right cusp presents early splitting into the RCA (which has a totally occluded proximal segment, R), the LAD, the diagonal branch (D), and a large septal artery (SEP). The paths of the two anomalous vessels (LAD and SEP) are parallel to each other and are clearly intraseptal, running posterior to the pulmonary artery, as best seen in the lateral projection (E), where a catheter is visible in the pulmonary artery. RC (view D) = right conal branch; RM (view F) = ramus medianus. F. Angiogram of the LCA, in the left anterior oblique projection, showing that the ostium in the left coronary sinus leads only to the circumflex artery and the ramus intermedius (RM). G. Schematic diagram of this case in the left anterior oblique projection. The three possible "anterior" anomalous courses of an LCA originating from the right sinus are superimposed for comparison (1, prepulmonic = crosses; 2, preaortic = squares; 3, intraseptal course, as seen in this case). D = diagonal artery; L = LAD; R = RCA; sp = septal artery.

CASE REPORT 4.31**RCA Arising From the Left Anterior Sinus and Following a Precardiac (or Prepulmonic) Path**

A 40-year-old hypertensive man with typical exertional angina underwent a treadmill electrocardiographic test that was negative for coronary artery disease. Coronary angiography revealed multiple significant lesions in the LAD. The nondominant RCA arose from the LAD and followed a precardiac path (Fig.

CR4.31, A–C). The circumflex artery was the dominant vessel, but it stopped at the posterior descending artery (PDA) (Fig. CR4.31, C). The patient underwent successful balloon angioplasty of the LAD. ■

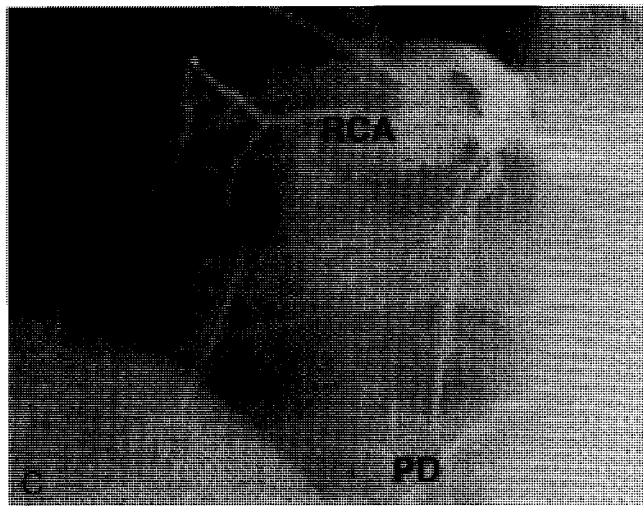
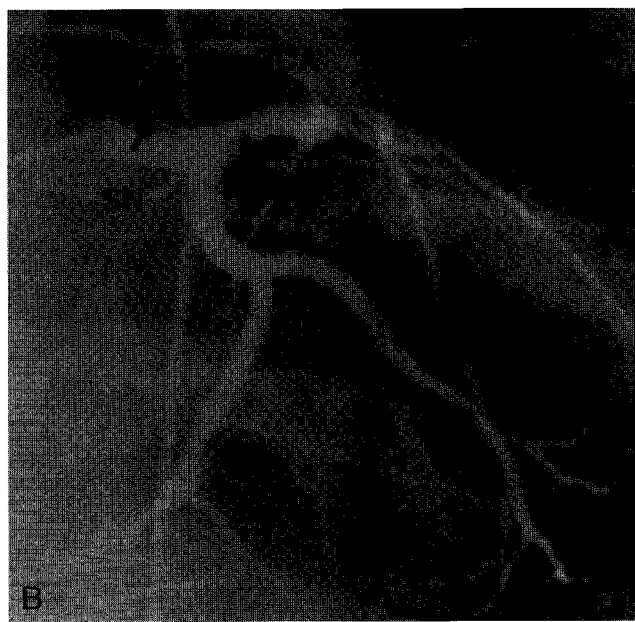
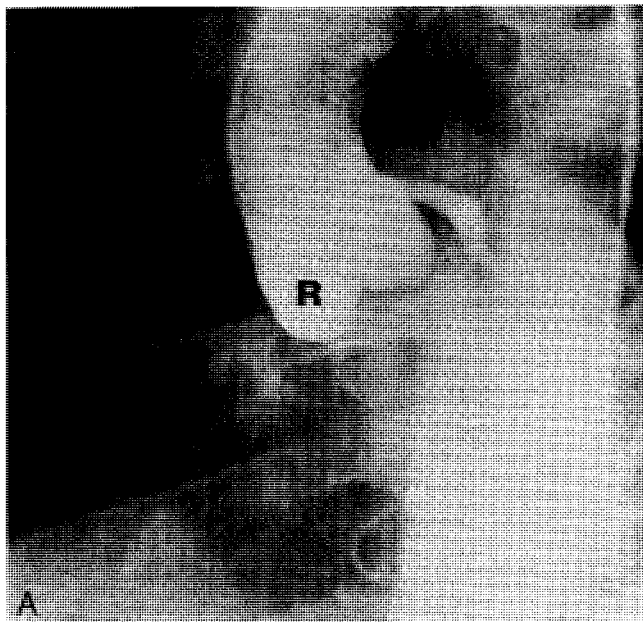


Figure CR4.31. A. Aortogram in the left anterior oblique projection, confirming that the right anterior sinus (view A, R) has no coronary ostia. Left coronary artery angiograms, in the posteroanterior (B) and left anterior oblique (C) projections, showing the RCA's anomalous origin and path. The sinus node artery (SN) originates from the mixed main trunk. The fact that the anomalous RCA's path is prepulmonic (not intraseptal) is indicated by both the anterior and the superior course and by the presence of a proximal infundibular (and anterior right ventricular) branch instead of a septal one (arrows). PD = posterior descending artery.

CASE REPORT 4.32

Anomalous Location of the Coronary Ostium in the Opposite Sinus: LAD Arising From the Right Sinus (via a Mixed Trunk) and Following a Prepulmonary (or Precardiac) Path

A 49-year-old man with hypertension, hyperlipidemia, and coronary artery disease was admitted because of angina at rest. Cardiac catheterization revealed two LAD arteries (split LAD): one that arose from the left sinus and had a 90% stenotic lesion, and the other (RAD) that arose from the right mixed trunk ("RCA")

and was free of disease (Fig. CR4.32, A–D). The circumflex artery originated anomalously from the proximal RCA and followed a retroaortic path. The patient underwent successful rotablation/angioplasty of the diseased LAD. ■

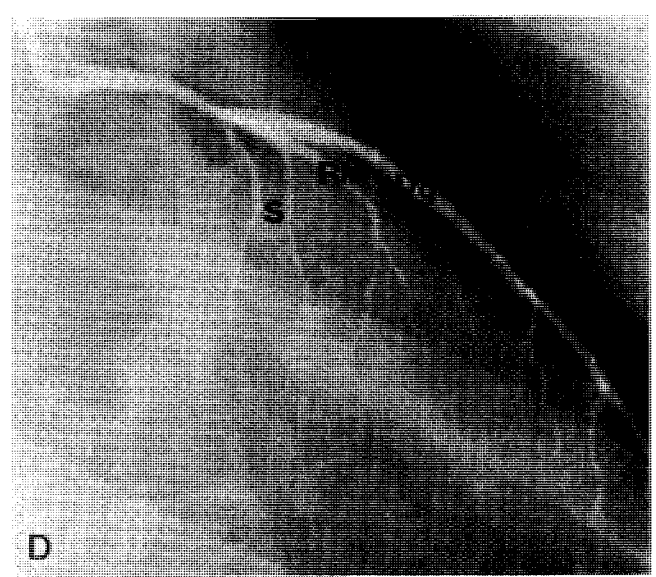
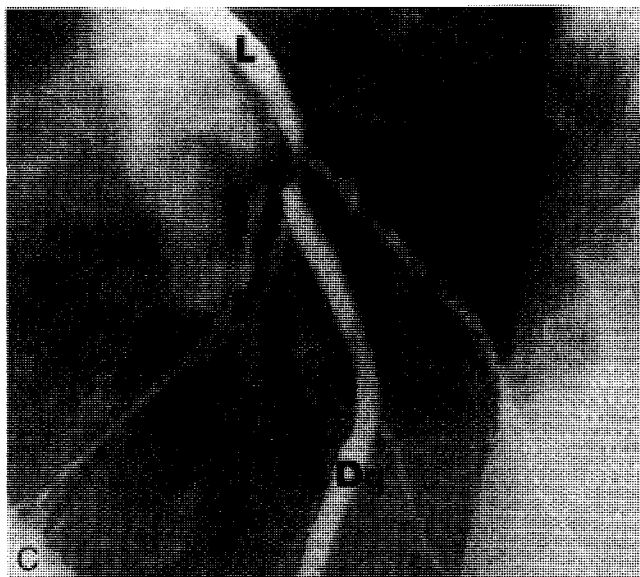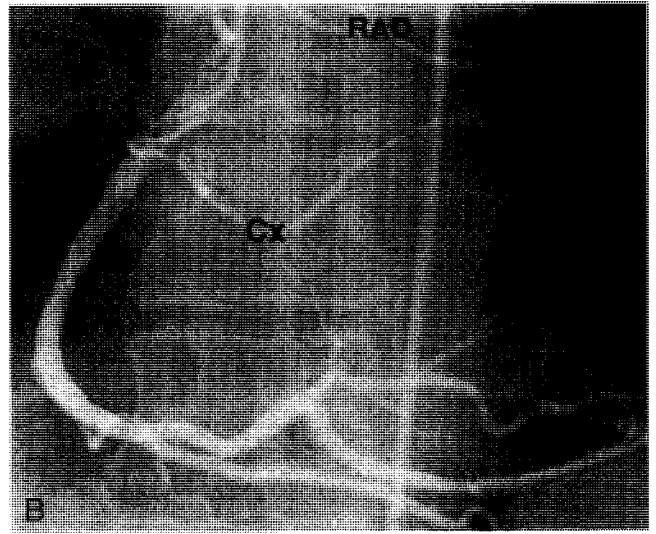
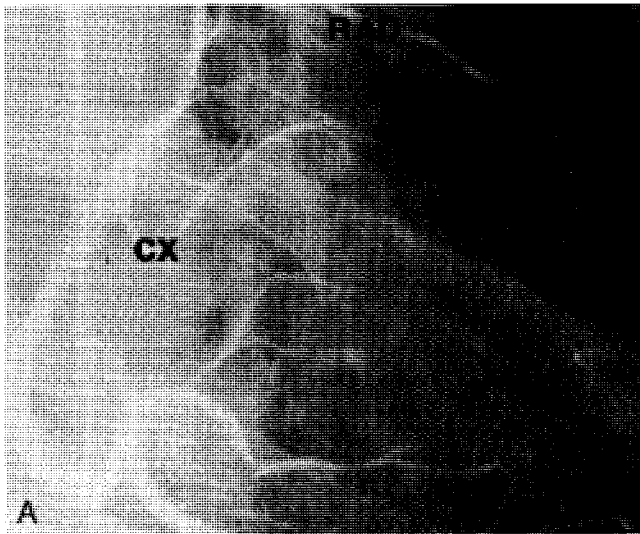


Figure CR4.32. Angiograms of the RCA, in the right anterior oblique (A) and posteroanterior (B) projections, showing a small "LAD" that arises from the RCA and supplies the lower interventricular septum. The RCA proper is dominant. Cx = circumflex artery; RAD = right anterior descending artery. C and D. Angiograms of the LCA, in the left (C) and right (D) anterior oblique projections. The main vessel (L) leads to two branches that serve the upper septum (S), a ramus medianus (RM) and a large diagonal (Dg) branch. Because the diagonal and septal branches belong to the LAD, the vessel should be labeled split LAD (with components from both the right and left coronary sinuses).

CASE REPORT 4.33**Anomalous Location of the Coronary Ostium in the Opposite Sinus: LCA Arising From the Right Sinus (via a Mixed Trunk) and Following a Prepulmonary Path (“Single Coronary Artery”)**

A 37-year-old male smoker presented with severe atypical chest pain associated with inversion of the inferior electrocardiographic T wave. Cardiac catheterization showed marked mitral

valve prolapse. The LCA arose from a right-sided mixed trunk (so-called “single RCA”) and followed a prepulmonary path (Fig. CR4.33, A–F). Medical treatment was recommended. ►

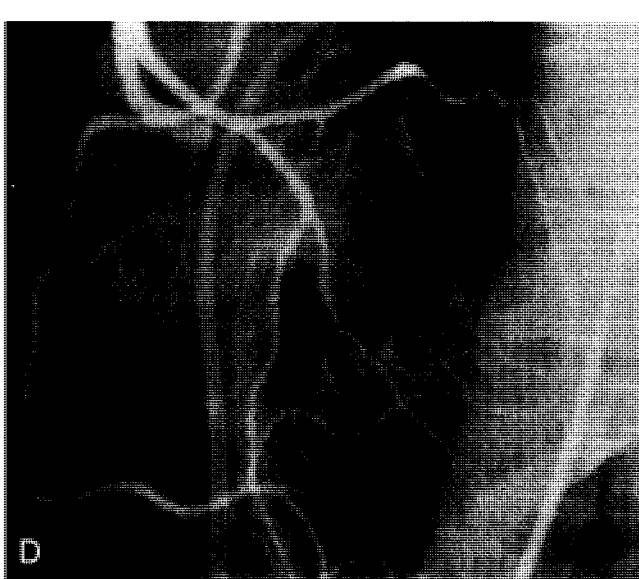
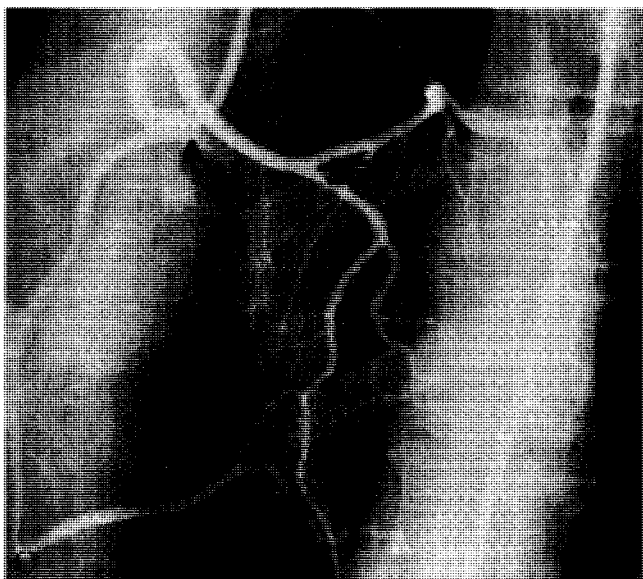
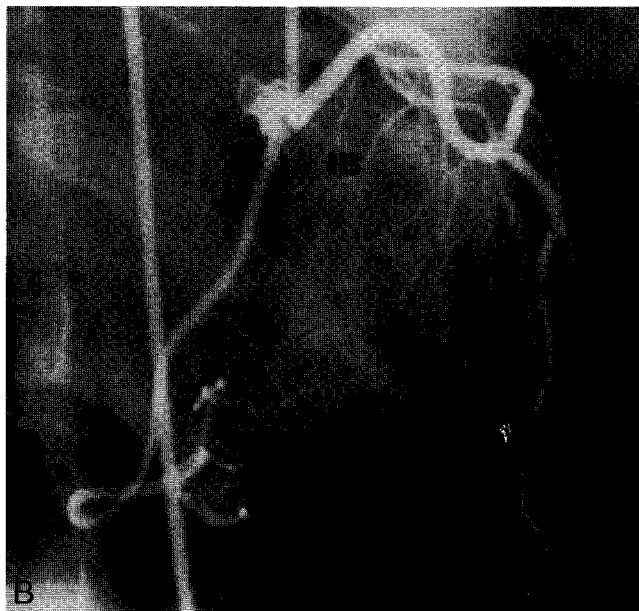
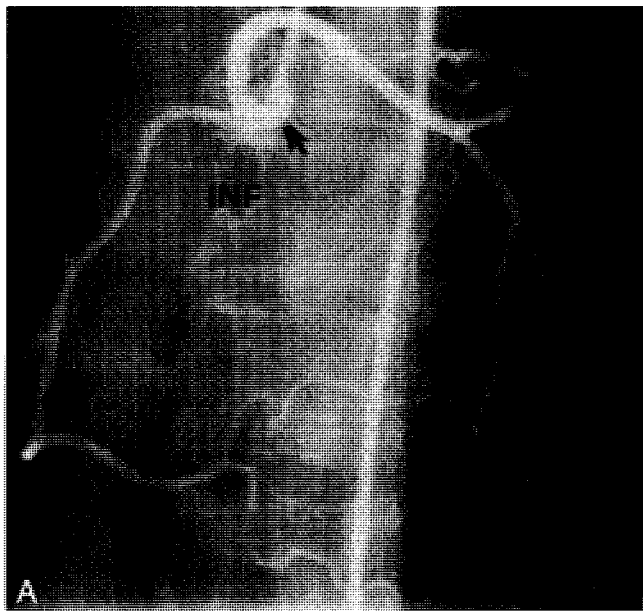


Figure CR4.33. Angiograms of the single coronary artery, in the posteroanterior (A), mildly cranial right anterior oblique (B), left anterior oblique (C), mildly cranial left anterior oblique (D), and lateral (E) projections. The undivided LCA trunk runs just in front of the expected site of the pulmonary valve (see view E, pulmonary catheter), and gives rise only to a small infundibular branch (INF, IB). The short, mixed trunk (single coronary ostium) is clearly evident (arrow). The proximal portion of the circumflex artery produces a septal branch (SEP). (continued)

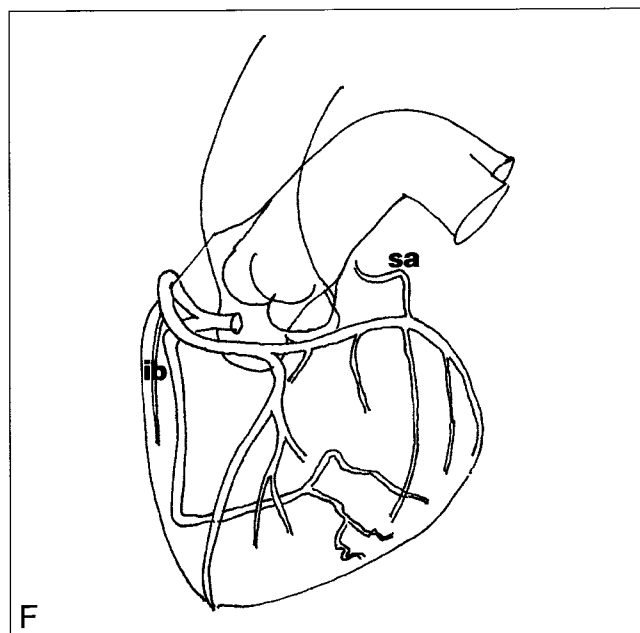
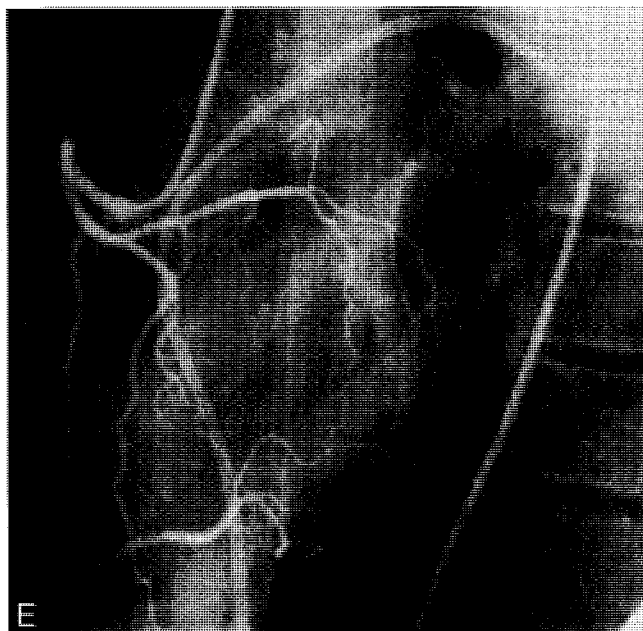


Figure CR4.33. (Continued) E. See legend on previous page. F. Schematic interpretation in the lateral projection. The sinus node artery (sa) originates from the circumflex artery at the origin of the obtuse marginal branch. ib = infundibular branch.

CASE REPORT 4.34**Atresia of the LAD Ostium Versus Origination of the LAD From the RCA/Posterior Descending Artery**

A 60-year-old male smoker with hypercholesterolemia and diabetes mellitus had a family history of sudden cardiac death. For several months, the patient had been experiencing fatigue and shortness of breath on moderate exertion. He had had no clinical or electrocardiographic evidence of a myocardial infarction. During the present admission, treadmill testing was terminated within less than 5 minutes because of dyspnea, but no electrocardiographic changes were observed. Cardiac catheterization revealed a significant stenosis of the proximal RCA (Fig. CR4.34, A). Atresia or occlusion of the proximal LAD was also documented; the rest of the LAD could be visualized only from the

RCA via its end-to-end anastomosis with the posterior descending artery (Fig. CR4.34, B and C). The patient underwent successful balloon angioplasty, followed by stenting of the proximal RCA (which may constitute a mixed trunk or a left main "equivalent" as classified by Roberts et al³²⁶).

Comment: The fact that, in this case, the LAD shows a single angiographic origin from the posterior descending artery, in the presence of normal left ventricular function, suggests that the proximal LAD interruption is a case of congenital atresia (prenatal) origin, not an acquired occlusion. ►

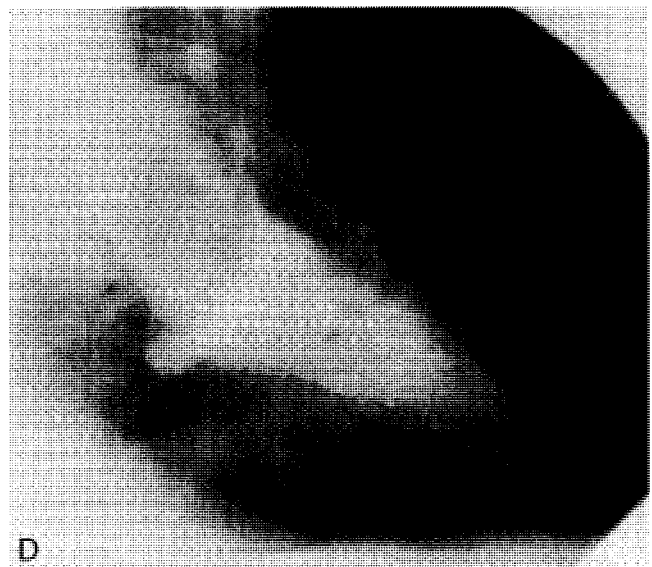
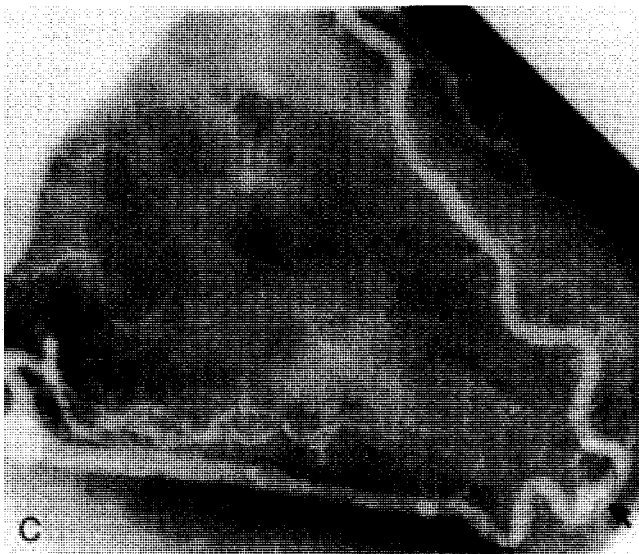
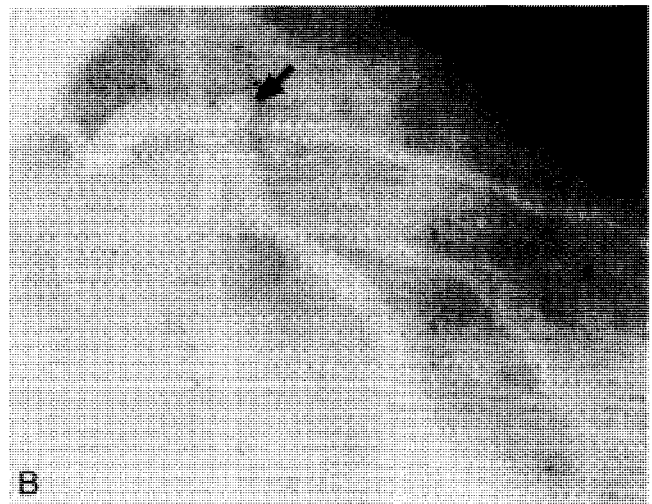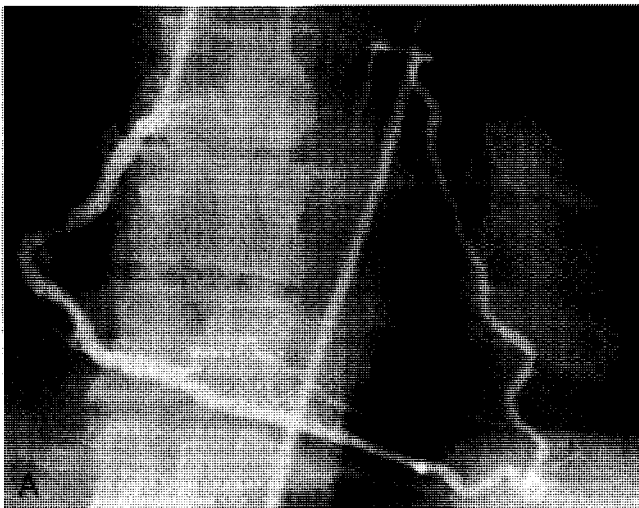


Figure CR4.34. See legend on next page

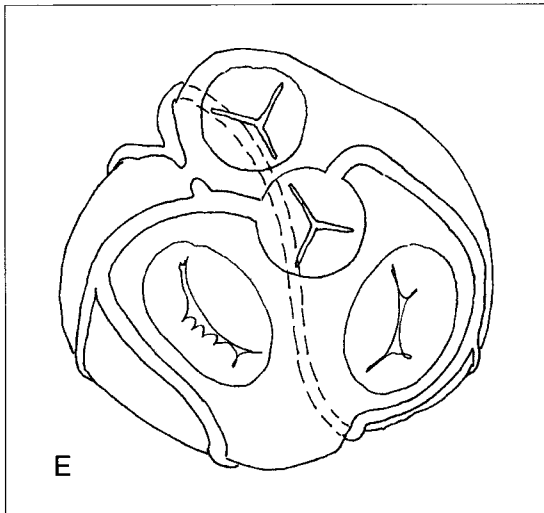


Figure CR4.34. **A.** Angiogram of the RCA, in the posteroanterior projection, revealing stenosis in the proximal portion of the RCA (equivalent to stenosis of the left main coronary artery) and a single communication between the posterior descending artery and the distal LAD. **B.** Angiogram of the LCA, in the right anterior oblique projection, showing a "nipple" that suggests the site of anatomic origin of the LAD (arrow), and an absence of homolateral collaterals to the LAD. **C.** Magnified angiogram of the RCA, in the right anterior oblique projection, showing continuity (arrow) between the RCA and the LAD without a change in diameter (as is usually seen in cases of acquired collaterals). **D.** Left ventricular angiogram in the right anterior oblique projection, revealing a normal end-systolic contour (without anteroseptal hypokinesia). **E.** Diagrammatic representation of the anomaly in the coronary plane.

CASE REPORT 4.35**Coronary (Pseudo) Hypoplasia**

A 40-year-old man with hypertension, hypercholesterolemia, and diabetes mellitus, had an abnormal baseline electrocardiogram. Exercise thallium scintigraphy suggested the presence of anterolateral ischemia. Cardiac catheterization revealed a “hypoplastic” distal LAD system, featuring a large diagonal branch and a dominant RCA whose posterior descending branch wrapped around the cardiac apex (Fig. CR4.35, A–C). Medical treatment was continued.

Comment: This abnormal coronary pattern is probably congenital and benign (not associated with ischemia or an increased risk of myocardial infarction). In this case, it did not appear to be responsible for the abnormal nuclear scintigram. In cases of acquired coronary artery disease, the LAD would not be bypassable. ■

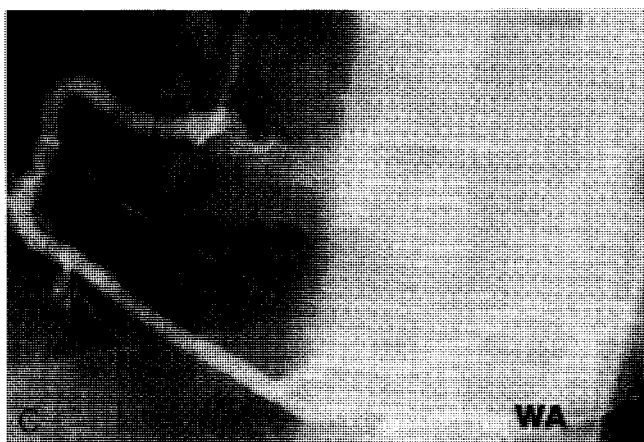
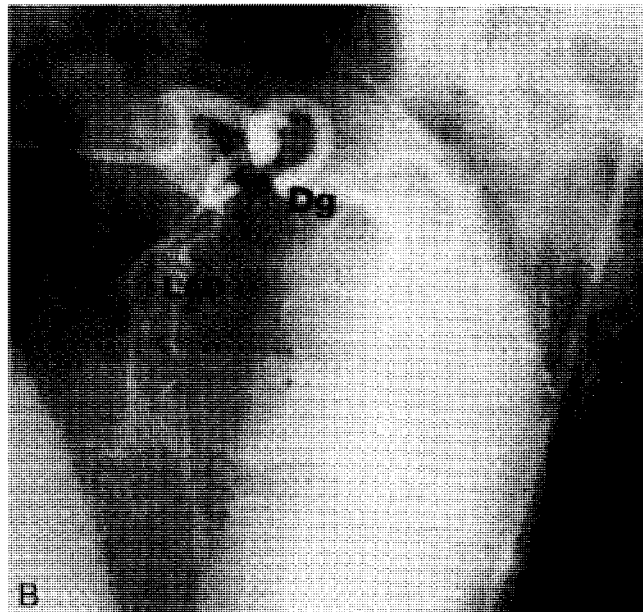
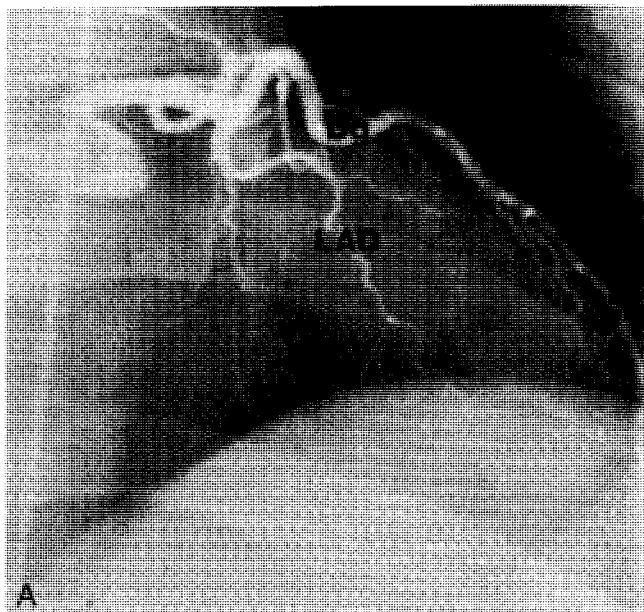


Figure CR4.35. Angiograms of the LCA, in the posteroanterior (A) and left anterior oblique (B) projections, showing a large diagonal branch (Dg) and a small postdiagonal LAD. C. Angiogram of the RCA, in the left anterior oblique projection, showing a large posterior descending branch that wraps around the cardiac apex (WA).

CASE REPORT 4.36

Intramural Coronary Artery (Muscular Bridge)

A 67-year-old hypertensive woman underwent coronary angiography because of atypical chest pain and increased risk factors for coronary artery disease. The study showed an intramural proximal-to-mid LAD segment, or muscular bridge, without signifi-

cant fixed obstructive disease (Fig. CR4.36, A-F). The left ventricle was moderately hyperkinetic (Fig. CR4.36G). The patient continued to undergo medical treatment for hypertension. ►

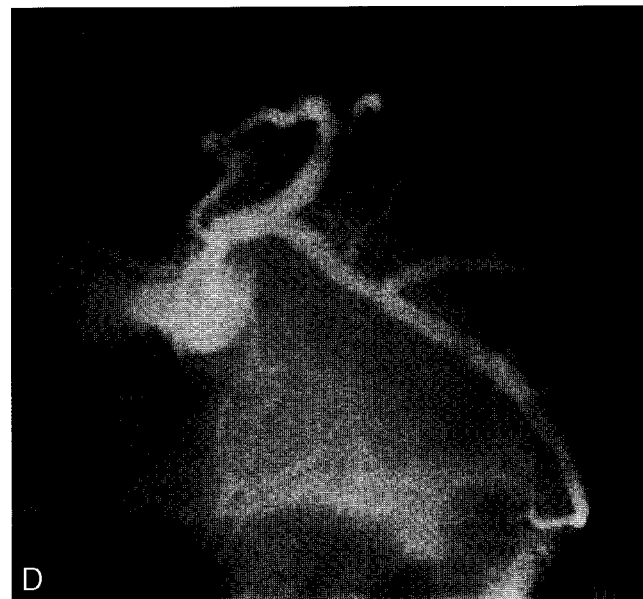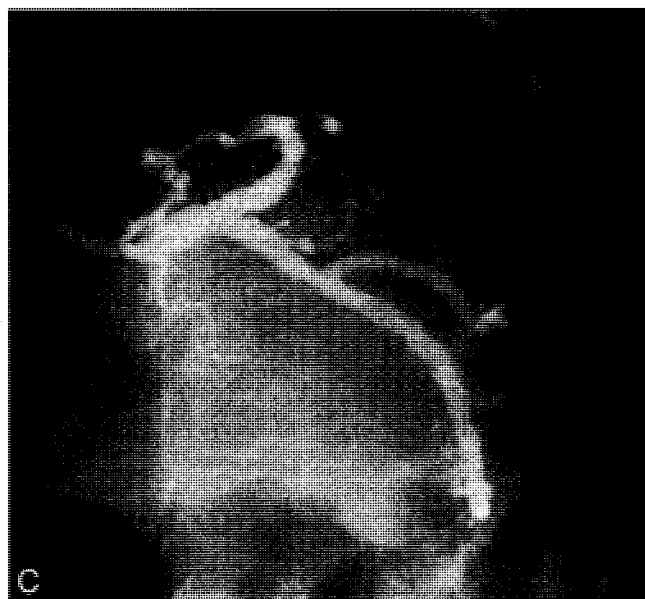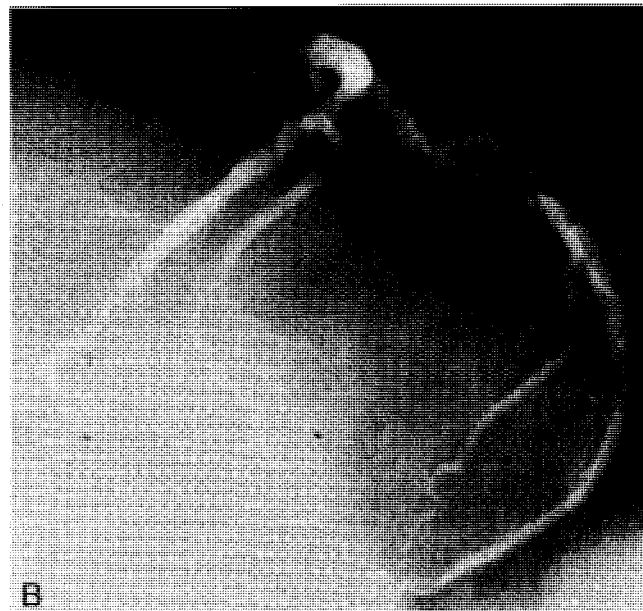
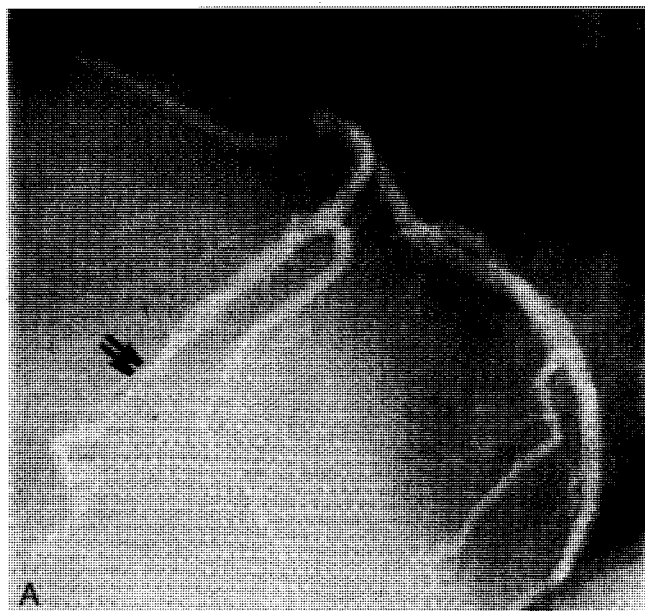


Figure CR4.36. Angiograms of the LCA, in the cranial left anterior oblique projection, during systole (A) and diastole (B). C and D. Angiograms of the LCA, in the caudal left anterior oblique projection, during systole (C) and diastole (D). continued

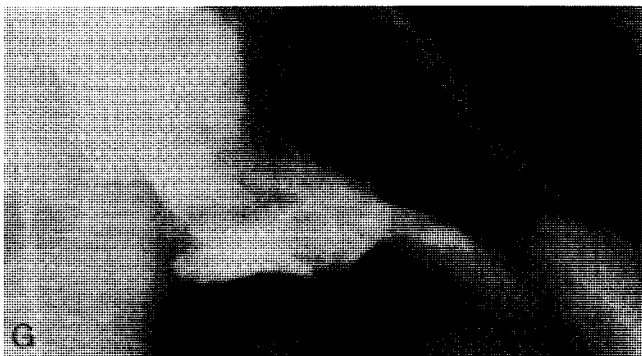
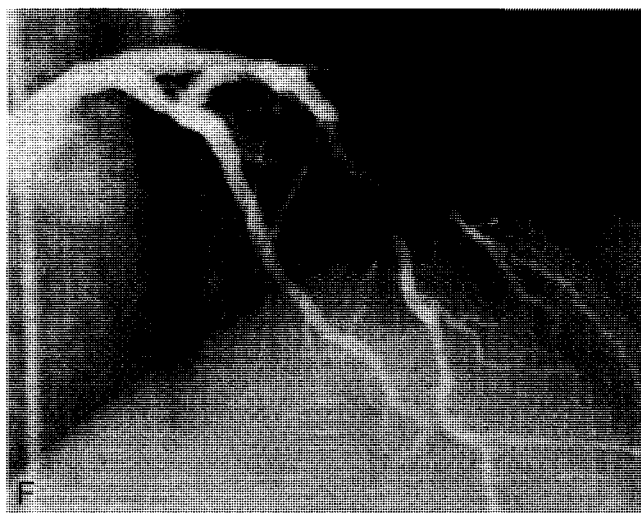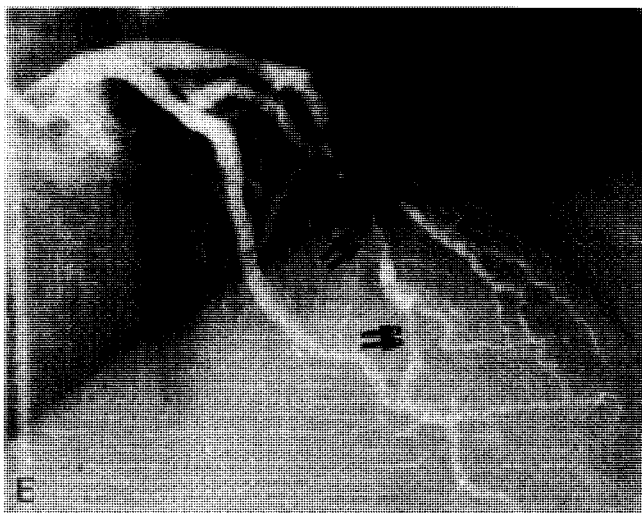


Figure CR4.36. (Continued) **E** and **F**. Angiograms of the LCA, in the right anterior oblique projection, during systole (**E**) and diastole (**F**). **G**. Left ventricular angiogram, in the right anterior oblique projection, showing a hyperkinetic left ventricle during end-systole. The systolic narrowing of the LAD's midsection is severe (80%), involving a relatively long segment of this artery (arrows, views **A**, **C**, and **E**).

CASE REPORT 4.37**Epicardial Crossing**

A 59-year-old woman, with significant risk factors for coronary artery disease, presented with unstable angina. Selective angiography showed no critical fixed coronary obstructive lesions. The

second obtuse marginal branch appeared to have a relatively large (2-mm diameter) branch that abnormally crossed the first obtuse marginal branch (Fig. CR4.37, A–C). ■

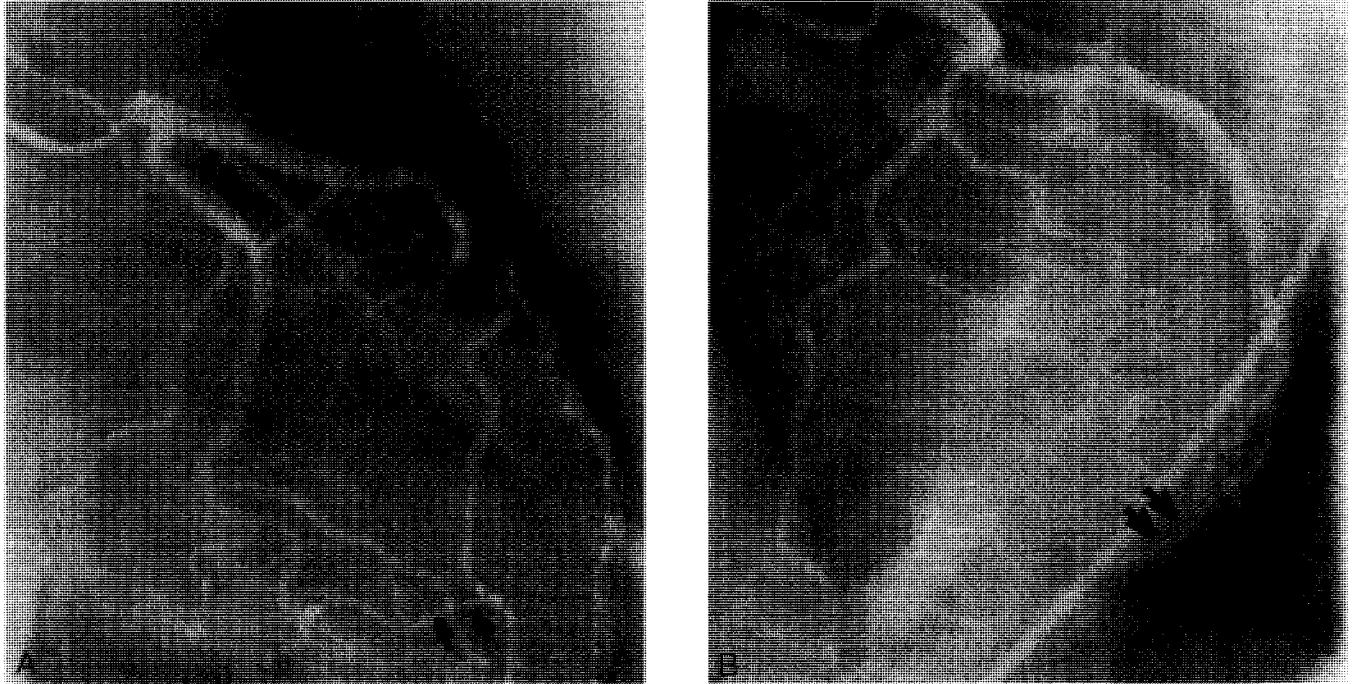


Figure CR4.37. Angiograms of the LCA in the right anterior oblique (**A**) and left anterior oblique (**B**) projections. The abnormally crossing, obtuse marginal branches (arrows) appear to be in the subepicardial space.

CASE REPORT 4.38**“Absent Posterior Descending Branch” (Split RCA)**

An 81-year-old man was admitted with a history of prolonged chest pain at rest. The pain had begun a few weeks earlier. Cardiac catheterization revealed occlusion of the mid LAD (not shown), with a mildly to moderately decreased ejection fraction. The RCA showed no significant coronary disease, but it had two

posterior descending branches (split RCA) (Fig. CR4.38). A rest-stress nuclear left ventricular performance study was significant only for mild inferior hypokinesia at peak stress, without changes in the LAD's territory. The patient was discharged from the hospital on a medical regimen. ■

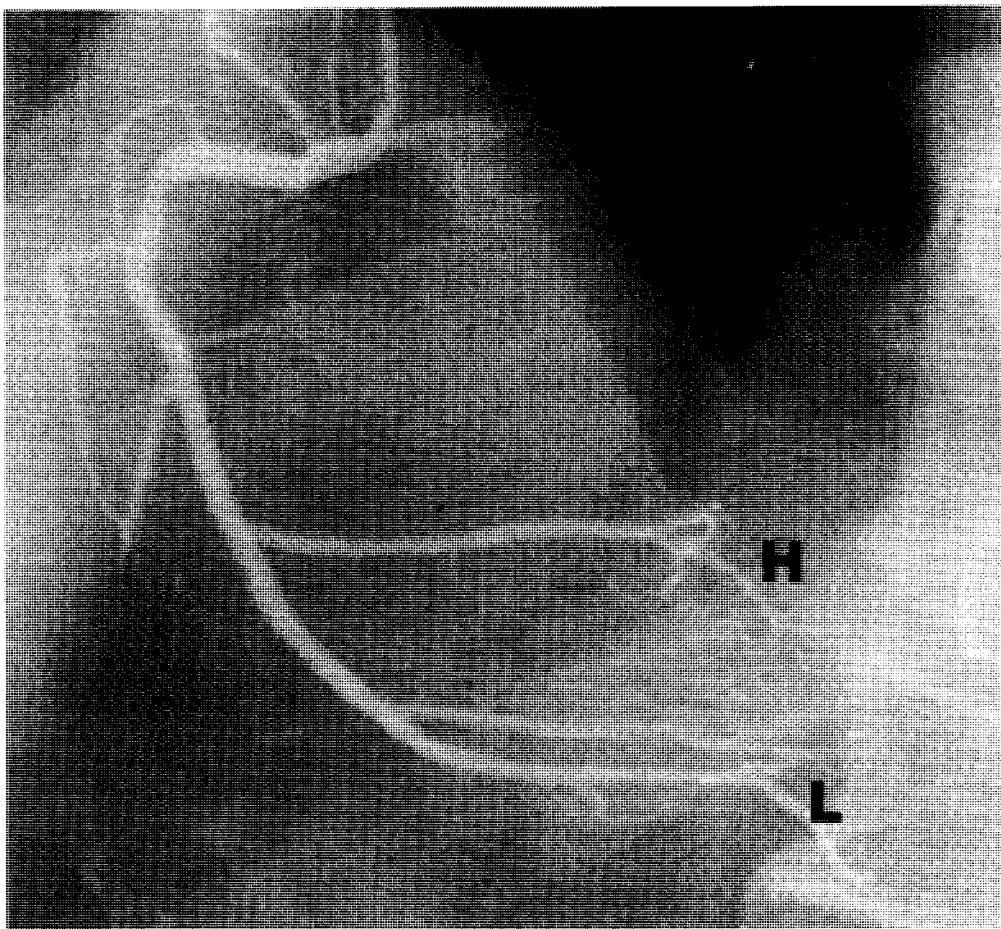


Figure CR4.38. Angiogram of the RCA in the cranial left anterior oblique projection. The high (H) posterior descending branch originates from the RCA, which courses in the distal atrioventricular groove. The low (L) posterior descending branch arises as the continuation of an abnormally large acute marginal branch and supplies the infero-apical portion of the ventricular septum.

CASE REPORT 4.39

“Absent Posterior Descending Branch” (Split RCA)

A 49-year-old man with diabetes mellitus and hypertension presented with a 1-month history of effort-related angina. Treadmill exercise testing showed borderline ischemia. Cardiac catheterization revealed that the proximal segment of the RCA split into two major branches, both supplying the posterior interventricular

septum (Fig. CR4.39, A–C). In addition, left coronary angiography showed a significant lesion in the diagonal branch (not shown). The patient underwent successful angioplasty of the lesions in the two distal branches of the RCA. ■

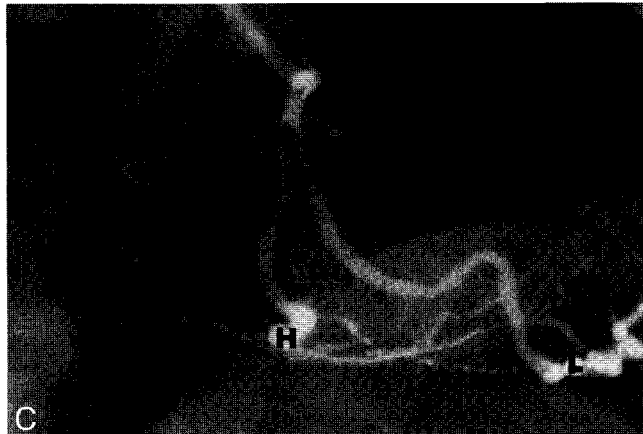
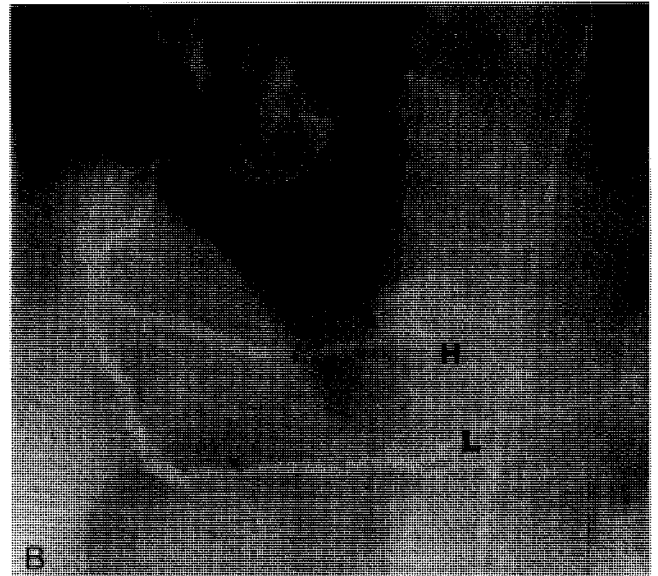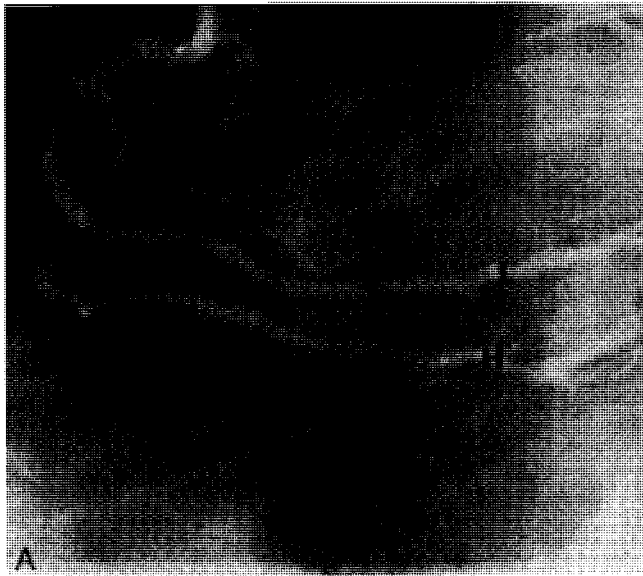


Figure CR4.39. Angiograms of the RCA in the caudal left anterior oblique (A), cranial left anterior oblique (B), and right anterior oblique (C) projections. The proximal segment of the artery splits into two major branches, both of which have significant focal lesions (view B, asterisks). The infero-basal portion of the ventricular septum is supplied by the high branch (H), located at the atrioventricular groove, as far as the crux. The infero-apical portion of the septum is supplied by the low branch (L) located at the lateral wall of the right ventricle, as far as the peri-apical posterior interventricular groove.

CASE REPORT 4.40**“Absent”/Split LAD: One LAD Originating From the LCA and the Other Originating From the RCA**

A 62-year-old woman with a history of aortic valve replacement underwent cardiac catheterization before having elective redo aortic valve surgery. Her RCA produced an epicardial vessel that coursed in the mid and distal portions of the anterior interventricular groove, and the proximal LAD ended prematurely in the proximal groove (Fig. CR4.40, A–C). The circumflex artery

originated anomalously from the proximal RCA and followed a retroaortic course. Echocardiography revealed normal left ventricular function. At the time of redo aortic valve surgery, no intervention was carried out on the anomalous coronary artery (no infarction was noted at the apex). ■

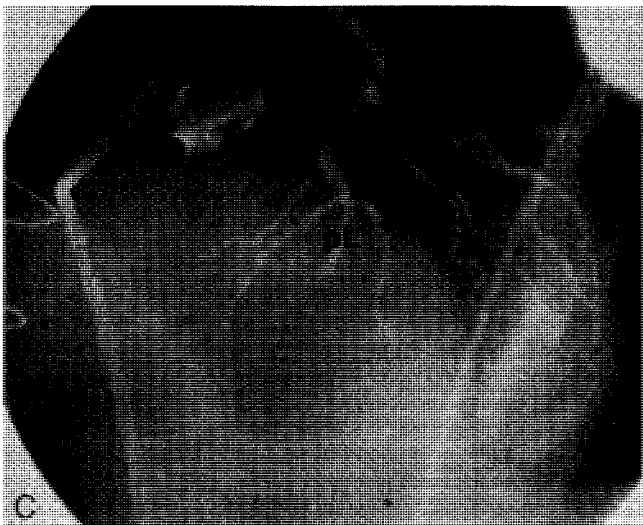
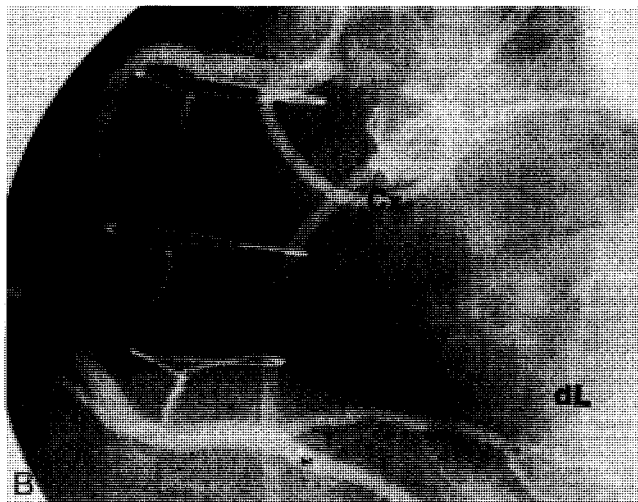
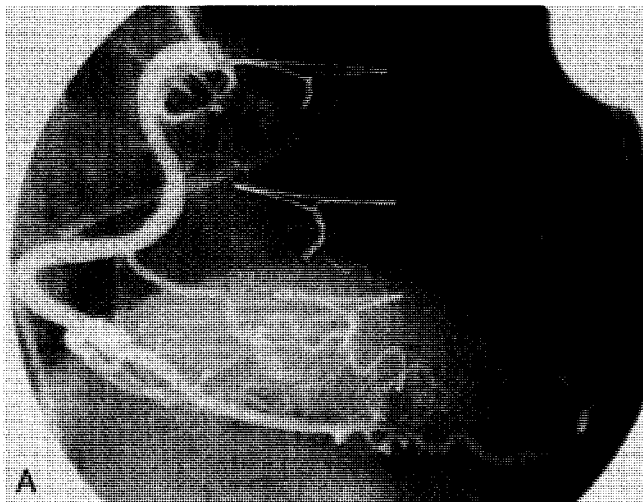


Figure CR4.40. Angiograms of the RCA in the right (A) and left (B) anterior oblique projections. The anomalous circumflex (Cx) and distal LAD (dL) arteries clearly originate from the proximal “RCA” (right mixed trunk) and the posterior descending artery, respectively. In view B, note the close proximity between the anomalous circumflex artery and the aortic prosthesis. C. Angiogram of the LCA, in the cranial left anterior oblique projection, showing the proximal LAD’s unusually short length (pL): beyond the origin of the second septal branch, the LAD ends in three small terminal branches. No collaterals are seen between the proximal LAD and the distal LAD. It is possible that the interruption of the LAD was caused by an acquired condition (not a congenital one); nevertheless, the absence of collaterals from the proximal LAD and the continuation of the posterior descending artery into the anterior (distal) descending artery, with gradual tapering as it ascends the anterior interventricular groove, in the absence of antero-apical scarring, support the theory that this was indeed a congenital variant (see also Case Report 4.34).

CASE REPORT 4.41

“Absent” Coronary Artery (LAD with Large Septal and Diagonal Branches)

A 55-year-old man with hyperlipidemia was admitted because of atypical chest pain and an abnormal treadmill test result. Selective coronary angiography showed a peculiar LAD pattern: the first septal branch was quite large and provided most of the anterior septal perforating branches (Fig. CR4.41, A and B); the diag-

onal artery was also large, reaching the apex with its terminal branch. No significant coronary obstruction was detected. The RCA (not shown) was dominant and normal. This coronary pattern fulfills the criteria for a “split LAD.” No intervention was considered necessary. ■

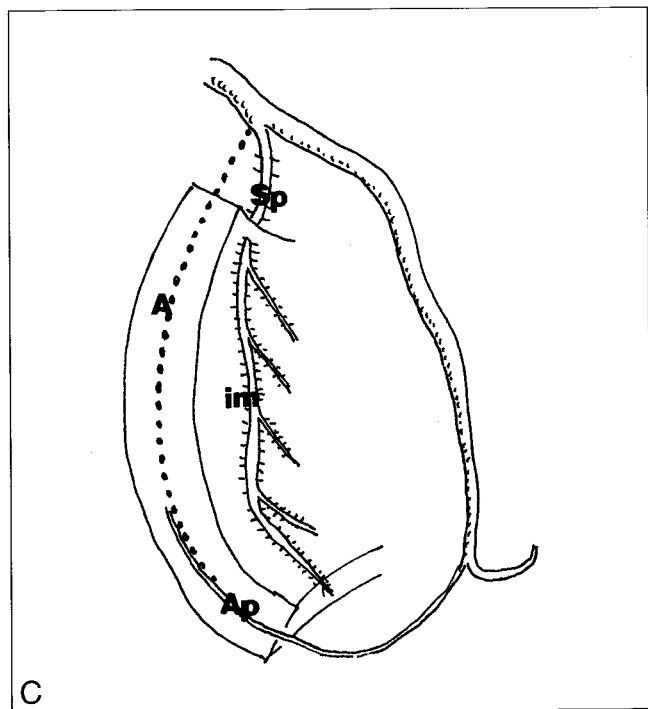
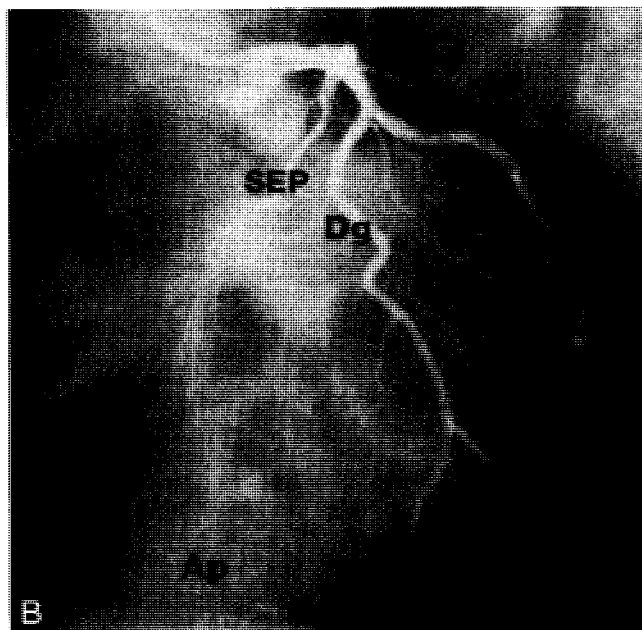
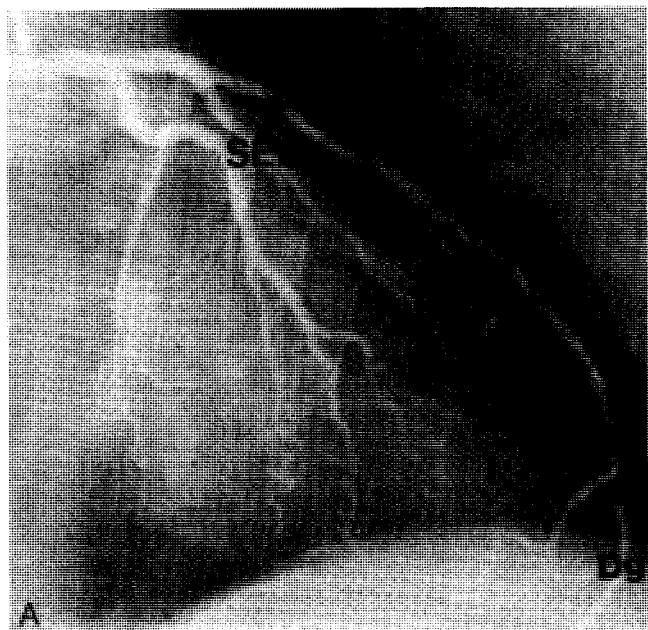


Figure CR4.41. Angiograms of the LCA, in the right (A) and left (B) anterior oblique projections. A large first septal branch (SEP) is present, but no anterior interventricular groove artery can be identified. The large diagonal artery (Dg) produces an apical branch (Ap). C. Diagrammatic representation of the anomaly. The dotted line represents the expected location of the “missing” LAD at the anterior interventricular groove. The area of the septum normally supplied by the LAD is in this case supplied by the large first septal branch and a recurrent apical branch of the large diagonal artery. A = expected site of epicardial LAD; im = intramural location; Sp = first septal branch.

CASE REPORT 4.42

Coronary Artery Fistula to the Right Ventricle

A 32-year-old policeman presented with recent-onset chest pain associated with diaphoresis. A treadmill thallium test showed mild anterolateral stress-induced ischemia and mild left ventricular dilation. At ages 7 and 12 years, the patient had undergone cardiac catheterization for a continuous precordial murmur, and a coronary fistula had been diagnosed. At that time, medical treatment was recommended because of the absence of symptoms and the evidence of a mild left-to-right shunt (1.1:1 pulmonary-to-systemic flow ratio). Cineangiograms obtained when the patient was 12 years old showed a fistula that arose from the proximal LAD and drained into the right ventricular outflow tract (Fig. CR4.42, A and B). Distal to the fistula, the LAD was small but patent. Left ventricular systolic function was normal.

On the present admission, physical examination was significant for a continuous murmur at the anterior precordium. Cardiac catheterization revealed significant left-to-right shunting ($Q_p:Q_s = 1:1.25$) at the level of the right ventricular outflow tract. Left ventricular angiography indicated that systolic function was diffusely impaired, with an ejection fraction of 40%. The proximal left main coronary artery had a mild, but definite, ostial stenosis related to the presence of a membrane-like structure (Fig. CR4.42C, arrows). The proximal trunk of the LAD showed a large aneurysmatic dilation (of the same diameter as the left anterior sinus), which ended in a short fistulous connection with the right ventricular outflow tract (Fig. CR4.42, D and E). AN = aneurysm; FS = fistula; PA = pulmonary artery; RVOT = right ventricular outflow tract. On left coronary angiography, the distal branches of the LCA were poorly filled, and the distal LAD and circumflex arteries were filled by means of collateral vessels (COLL) from the RCA (Fig. CR4.42F). These collaterals had not been seen on the angiogram obtained at age 12 (Fig. CR4.42B). The pressure in the proximal LAD was obtained by advancing a left coronary Amplatz-II guiding catheter over a 0.001-inch guidewire. The pressure looked ventricularized, with a diastolic value of about 20 mm Hg. Figure CR4.42G shows a schematic diagram of the coronary anomaly.

At corrective surgery, the LAD aneurysm was entered to ligate the fistulous tract to the right ventricle. A 1-mm probe could not be passed into the small distal portion of the LAD. Therefore, the left internal mammary artery was implanted into the distal LAD (1-mm diameter), and a vein graft was inserted between the aorta and the ramus medianus (2.5-mm diameter). The circumflex artery was entered with a 1-mm probe but was not bypassed. An ostial ridge on the aortic left coronary ostium was resected.

The patient recovered uneventfully but, 1 month after surgery, he presented with an episode of prolonged chest pain, accompanied by electrocardiographic T-wave changes and mild creatine phosphokinase elevation. New angiograms (Fig. CR4.42, H–L) showed the disappearance of the earlier left main ostial membrane, filling of the small circumflex system, and distal obstructive disease of the obtuse marginal branch (view H). This disease was interpreted as evidence of recent distal clot embolization, probably from the aneurysmatic left main trunk. The vein graft to the ramus medianus was patent (view I), but the left internal mammary artery implant had a critical stenosis (arrow) at the distal anastomosis (views J and K). The distal LAD had a much larger diameter than on the preoperative angiogram, and multiple new collateral vessels connected the LAD with the lower left pulmonary artery. Angiography of the RCA (view L) revealed an absence of collaterals (arrows), and the RCA had a normal diameter.

The patient underwent angioplasty of the distal left internal mammary artery anastomosis with a 2.5-mm balloon catheter, followed by insertion of a 3.0-mm stent (NIR ON; SCIMED, Boston Scientific, Boston, Massachusetts, USA).

This case clearly illustrates the possible complications that may be associated with the natural course of a medium-sized coronary artery fistula: aneurysmatic dilation (with the potential for distal embolization of mural thrombus before and after repair of the fistula) and distortion of the coronary anatomy resulting from different rates of growth of the different coronary segments (see the ostial obstructions of the left main coronary artery and distal branches). ►

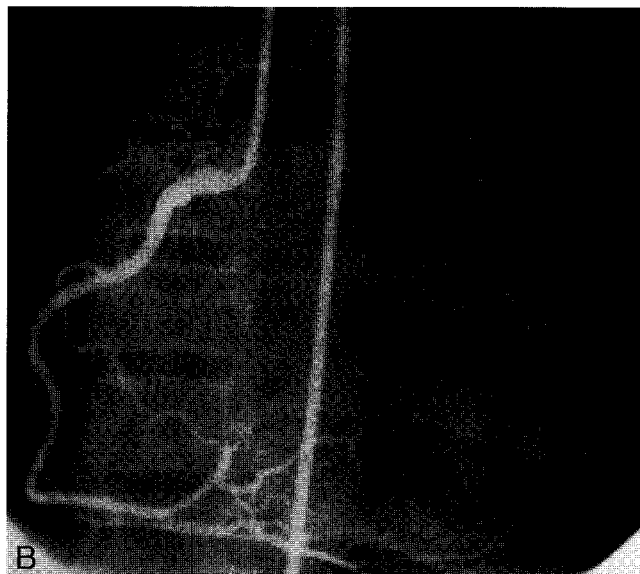
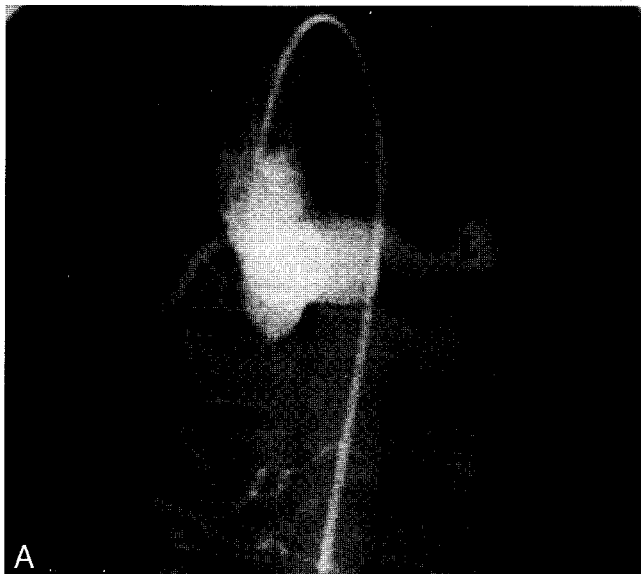


Figure CR4.42. A. Posteroanterior aortogram obtained at age 12 years, showing the ectatic left main and proximal LAD arteries, with a poorly visualized (in this photo) fistula from the LAD (L) to the right ventricular infundibulum. B. Angiogram of the RCA in the posteroanterior projection, obtained at age 12 years, showing no ectasia or collateral flow to the LCA. (continued)

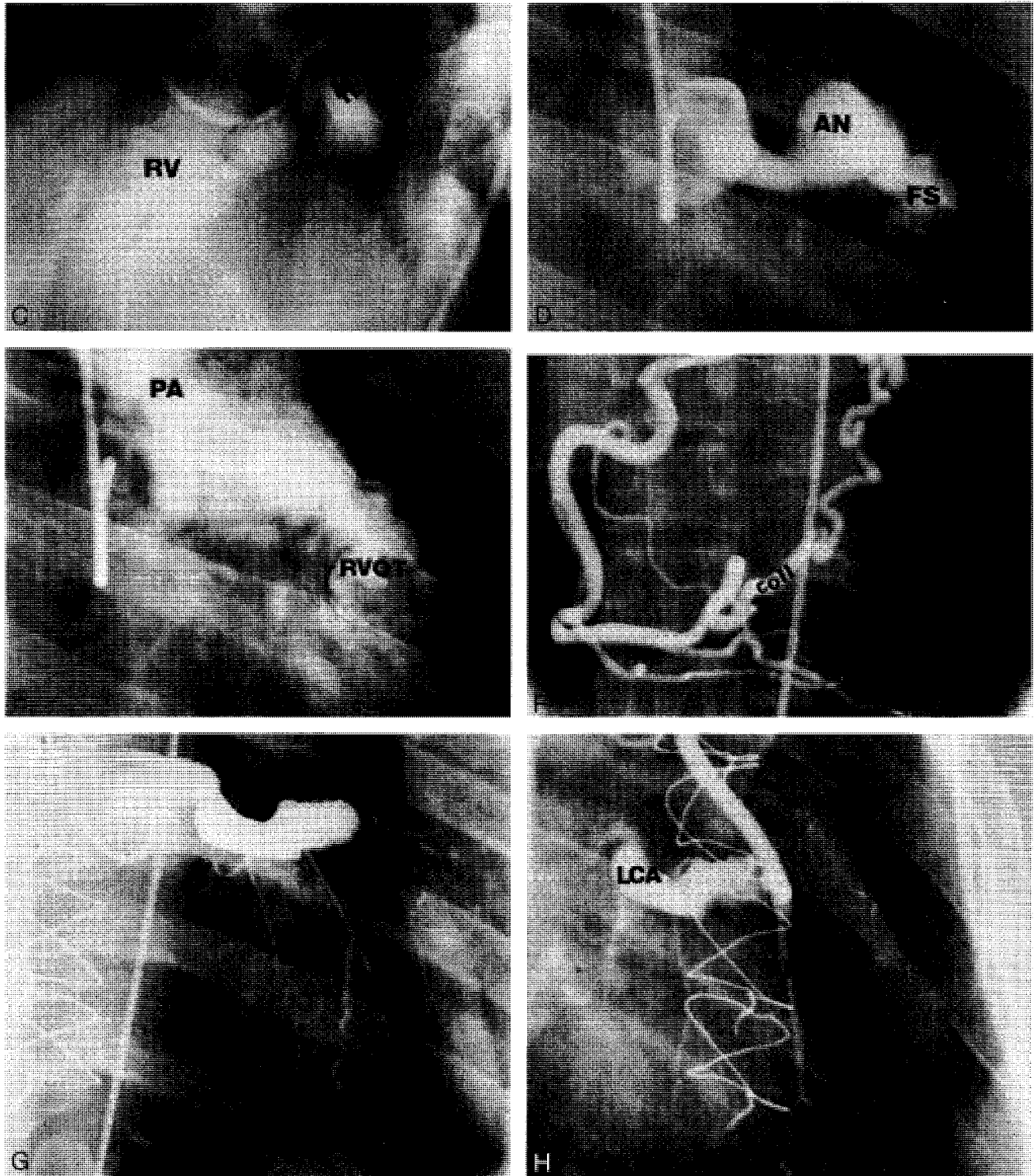


Figure CR4.42. (Continued) **C.** Angiogram of the LCA at age 32 years, in the cranial left anterior oblique projection, showing the ostial membrane-like stenosis and the LAD to right ventricular (RV) fistula. **D** and **E.** Angiogram of the LCA in the right anterior oblique projection, clearly showing the fistulous tract (FS) in the early phase (**D**) and the right ventricular outflow tract (RVOT) in the late phase (**E**) of the injection. AN = aneurysm; FS = fistulous orifice; PA = pulmonary artery. **F.** Angiogram of the RCA in the posteroanterior projection, showing diffuse ectasia and a rich collateral network to the circumflex (COLL) and LAD. **G.** Angiogram of the LCA in the right anterior oblique projection, showing persistent ectasia and poor runoff into the diminutive circumflex system, which contains newly apparent distal stenoses (asterisks) with sluggish runoff. **H.** Ramus medianus (RM) vein graft, in the right anterior oblique projection, showing good runoff and backup filling of the LCA. (continued)

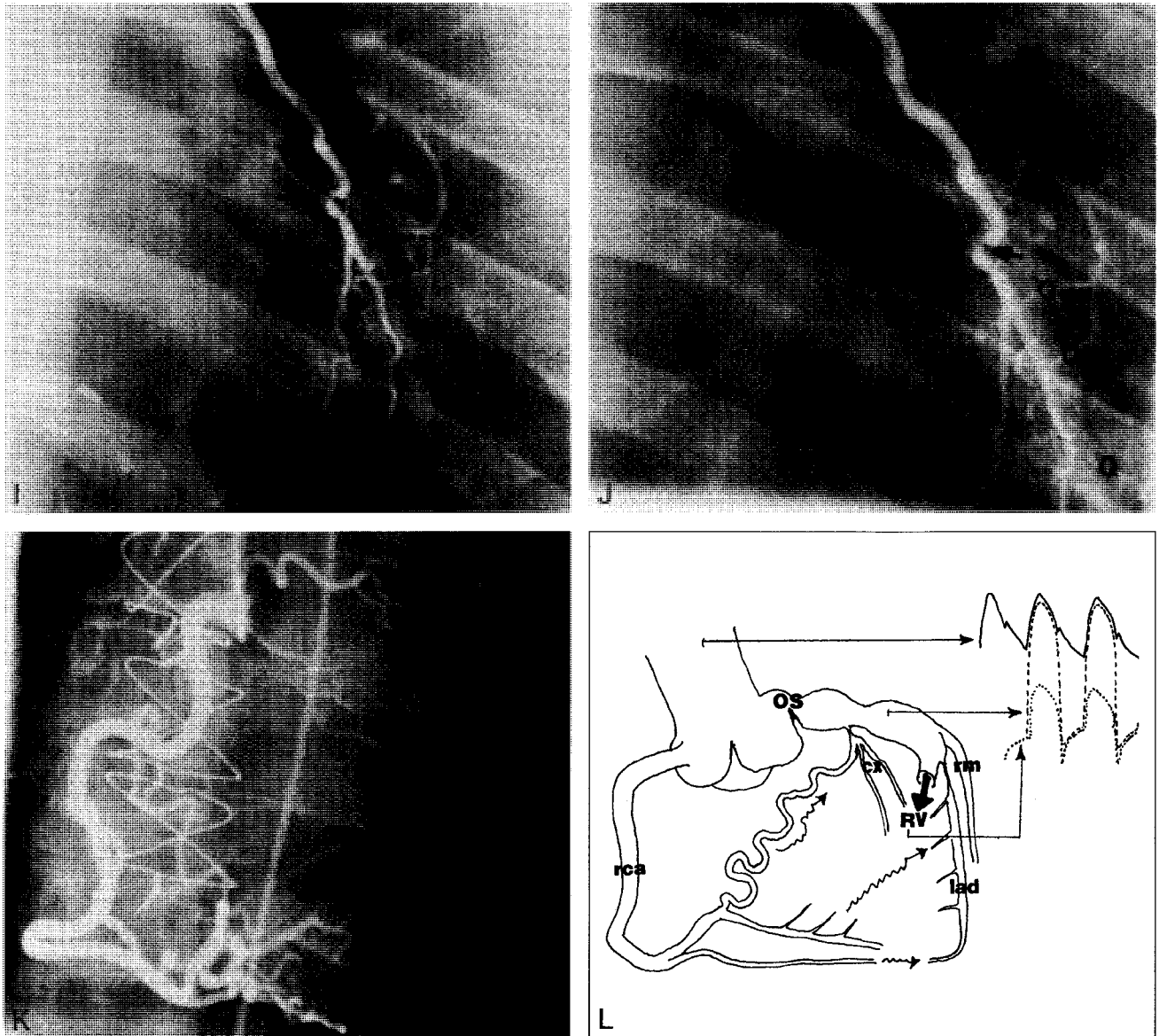


Figure CR4.42. (Continued) I and J. Left internal mammary artery graft to the LAD, in the right anterior oblique projection, showing distal anastomotic stenosis (arrow) and multiple newly formed collaterals (Q) leading from the LAD to branches of the left-lower-lobe pulmonary artery. K. Angiogram of the RCA in the posteroanterior projection, showing the absence of collateral filling of LCA branches (arrows). The size of the RCA has decreased since preoperative angiography. L. Diagram of the preoperative coronary anatomy and physiology, with a simulated rendering of the pressure tracings obtained at the following sites proximal and distal to the fistulous tract (arrow): aorta (driving source), LAD (direct source), and RCA (receiving cavity). Abbreviations as above; OS = ostial stenosis.

CASE REPORT 4.43**Coronary Ectasia with Multiple Coronaro-Cameral Fistulas**

A 64-year-old man, who had previously had a myocardial infarction and a transient ischemic attack, presented as a candidate for repair of an abdominal aortic aneurysm. Cardiac catheterization showed coronary ectasia, occlusion of the distal circumflex artery, and extensive coronaro-cameral fistulas to the right ventricle (Fig. CR4.43, A–E). The patient had diffuse proximal coronary ectasia that appeared excessive with respect to the amount

of fistulous flow, although it was certainly related to such flow. It is possible that the distal circumflex was also originally involved in the fistulous communications but eventually became thrombosed. The obtuse marginal artery is the only branch without fistulous involvement. Medical treatment was continued after the patient underwent uncomplicated repair of the abdominal aortic aneurysm. ►

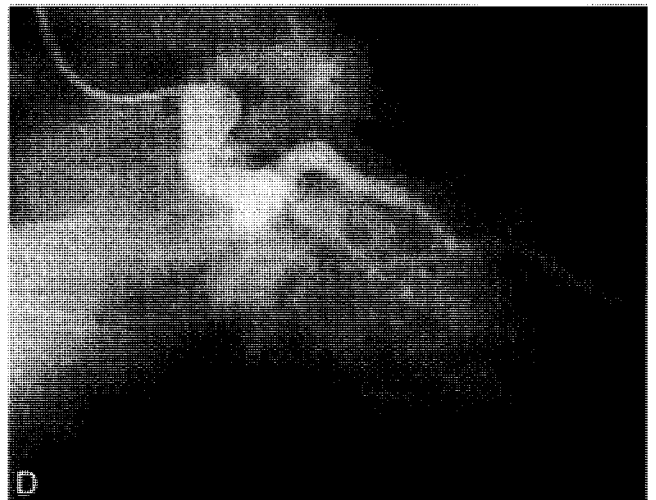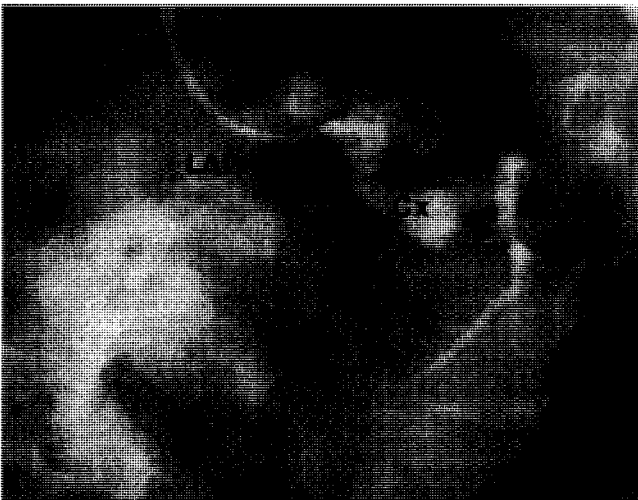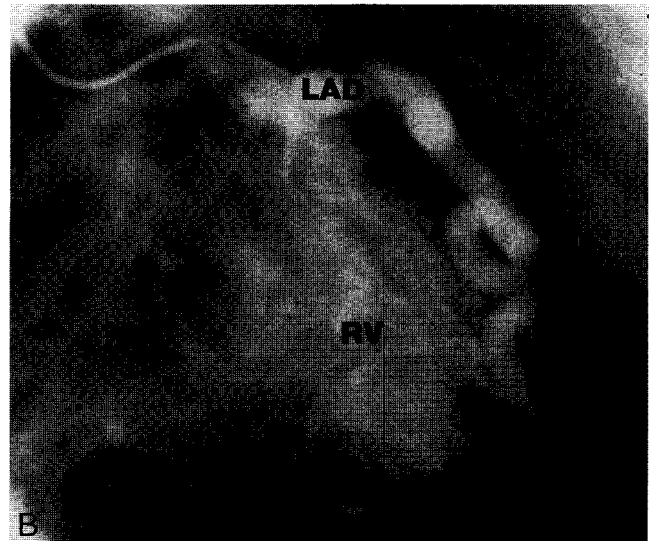
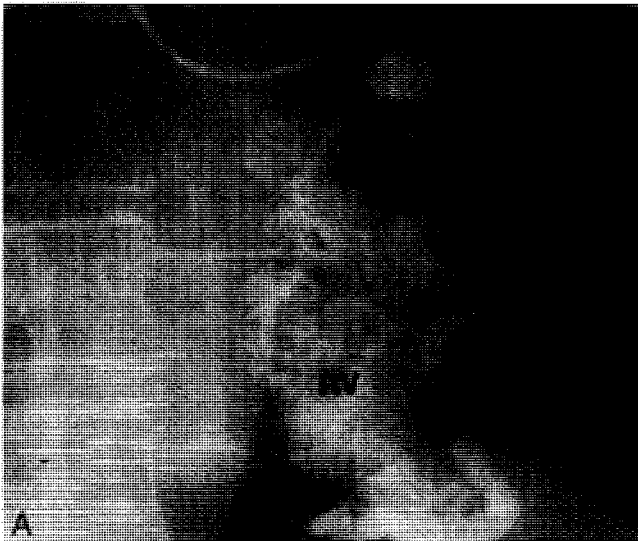


Figure CR4.43. Selective angiograms of the LAD in the posteroanterior (A) and right anterior oblique (B) projections. RV = right ventricle. Because of the very short left main trunk and the severe diffuse coronary ectasia, subselective catheterization of both major left arteries (the circumflex and LAD) was necessary. C and D. Selective angiograms of the circumflex artery (Cx) in the left (C) and right (D) anterior oblique projections (see text above). (continued)

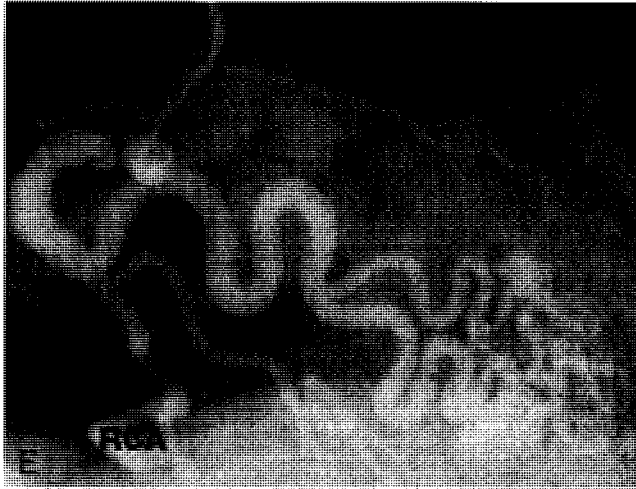

Figure CR4.43. (Continued) **E.** Angiogram of the RCA, in the right anterior oblique position, showing that the large anterior right ventricular branch and the proximal RCA are quite ectatic and carry most of the fistulous flow, while the distal RCA seems to have a normal luminal size.

CASE REPORT 4.44**RCA to Right Ventricular Fistulas Secondary to Multiple Right Ventricular Biopsies**

A 55-year-old man, who had had an orthotopic heart transplant because of ischemic cardiomyopathy, underwent an annual post-transplant cardiac catheterization procedure. Right coronary angiography showed a coronary-to-right ventricular fistula that had not been present on the first posttransplant angiogram. Postoperatively, the patient had had several right ventricular biopsies, which resulted in the acquired fistula. No intervention was necessary for this acquired coronary anomaly.

Comment: The fact that an acquired fistula causes coronarocameral drainage from adjoining coronary branches may suggest that collateral branches have been activated by the right ventricular (low-pressure) run-off. This phenomenon might be relevant for interpreting the frequent angiographic finding of multiple sources (by neighboring coronary branches) also for coronarocameral fistulas of congenital origin. ■

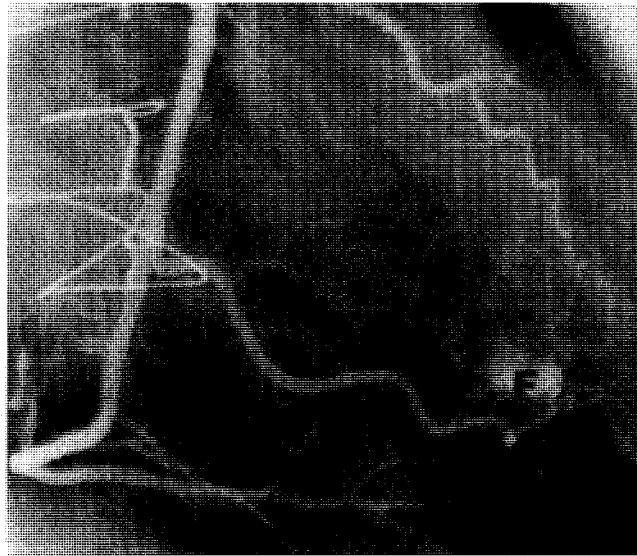


Figure CR4.44. Angiogram of the RCA in the right anterior oblique projection. A small coronary to right ventricular fistula (F) is clearly seen to fill from a proximal and a distal right ventricular branch.

CASE REPORT 4.45

Double Coronary Artery Fistulas to the Coronary Sinus

A 51-year-old man was evaluated for cardiovascular disease after experiencing acute dyspnea, diaphoresis, and atypical chest pain. A heart murmur was detected, and cardiac catheterization revealed two fistulas (Fig. CR4.45, A–C), one arising from the circumflex artery and the other arising from the RCA, both of which drained into the coronary sinus. The patient was treated with coumadin. Because his exertional dyspnea worsened, he sought a second opinion 6 months after the first evaluation. Physical examination was significant for a 2/6 systolic ejection murmur and a 1/6 diastolic murmur at the left sternal border. Echo-

cardiography showed a dilated coronary sinus, with an increased flow velocity across the coronary sinus into the right atrium. The right atrium and right ventricle were mildly dilated, and the pulmonary artery pressure was normal. The pulmonary-to-systemic flow ratio was calculated at between 1.8 and 2.1. Coronary angiography confirmed the presence of circumflex artery and RCA fistulas that drained jointly into the coronary sinus (Fig. CR4.45, D). A sestamibi treadmill test was negative for ischemia or myocardial scarring. The patient underwent successful elective ligation of both distal feeding arteries. ■

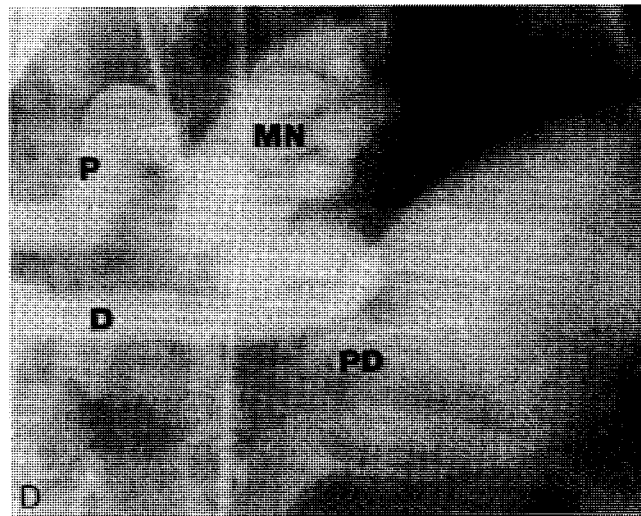
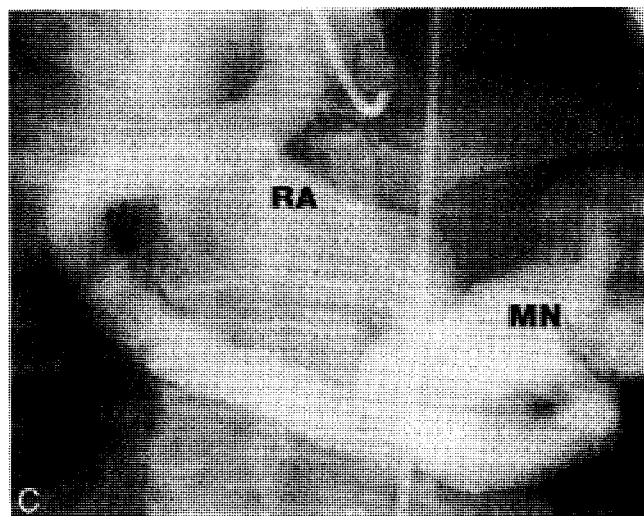
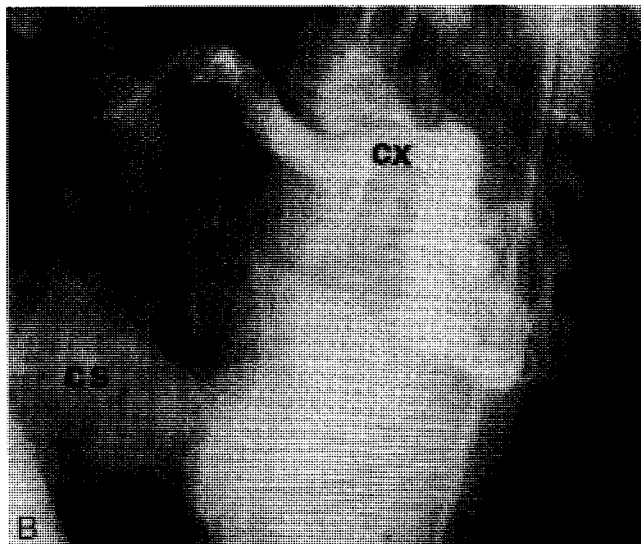
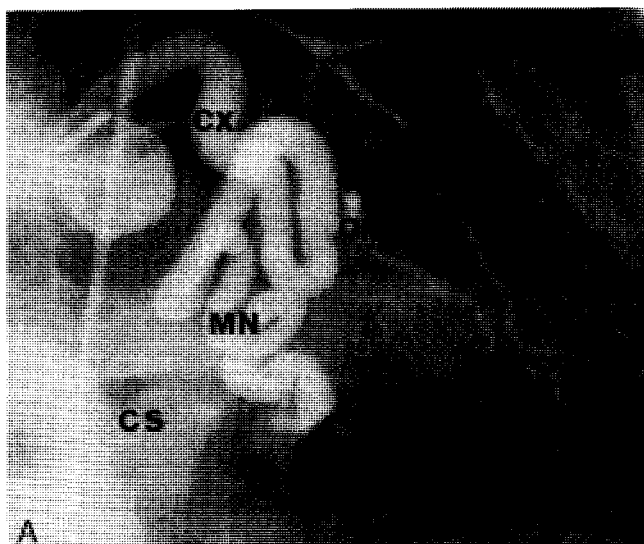


Figure CR4.45. Angiograms of the LCA in the posteroanterior (A) and left anterior oblique (B) projections, showing the greatly enlarged (6- to 8-mm) left main and circumflex arteries, as well as meandering (MN) tortuosity (view A, *) of the distal circumflex (Cx) artery before its entry into the coronary sinus (CS). The LAD (view B) and the obtuse marginal (view A, OM) branch are somewhat smaller than average. Early (C) and late (D) angiograms of the RCA, in the posteroanterior projection, show aneurysmatic dilation of the entire artery, which ranged from 10 to 12 mm in diameter; the artery followed a meandering, tortuous distal course before draining into the coronary sinus next to the fistulous termination in the circumflex artery. In view C, the right atrium (RA) is well visualized. MN = meandering tortuosity of the RCA. In view D, the posterior descending artery (PD) appears smaller than expected. D = distal RCA; P = proximal RCA.

CASE REPORT 4.46**Coronary Artery Fistula to the Coronary Sinus**

A 36-year-old woman had an orthotopic heart transplant because of ischemic cardiomyopathy. At her first annual postoperative evaluation, right-sided cardiac pressures were within normal limits, with no step-up in oxygen saturation. Coronary angiography showed an aneurysmal RCA with a moderate-sized fistula that drained into the coronary sinus (Fig. CR4.46, A). The posterolateral branch of the RCA was occluded, and it filled from the left coronary system (Fig. CR4.46, B). At the coronary sinus, the ostium of the fistula seemed partially obstructed. Left ventricular function was normal. Medical treatment was recommended.

Comment: This fistula was apparently not noted by the transplant surgeons, nor was it accompanied by a continuous murmur. Most likely, earlier in the donor patient's life, the fistula was probably larger, and it eventually underwent a spontaneous process of distal obliteration, possibly during the transplant procedure. Alternatively, the fistulous tract was indeed acquired and a sign of inadvertent surgical trauma, although this is unlikely. ■

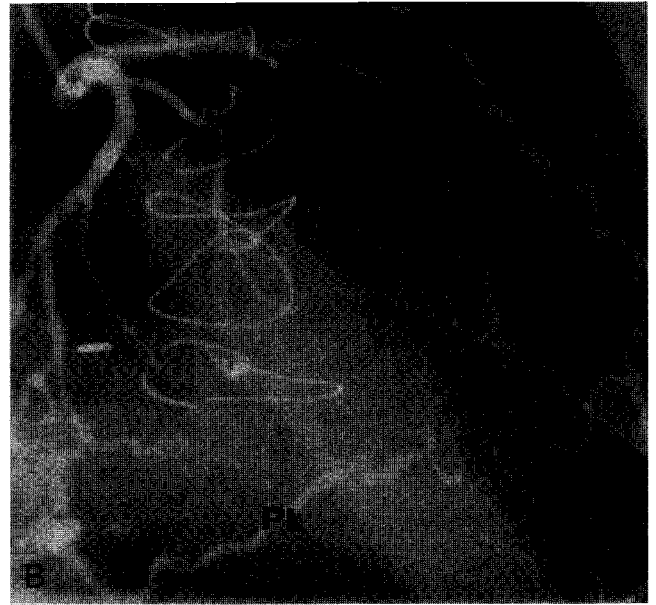
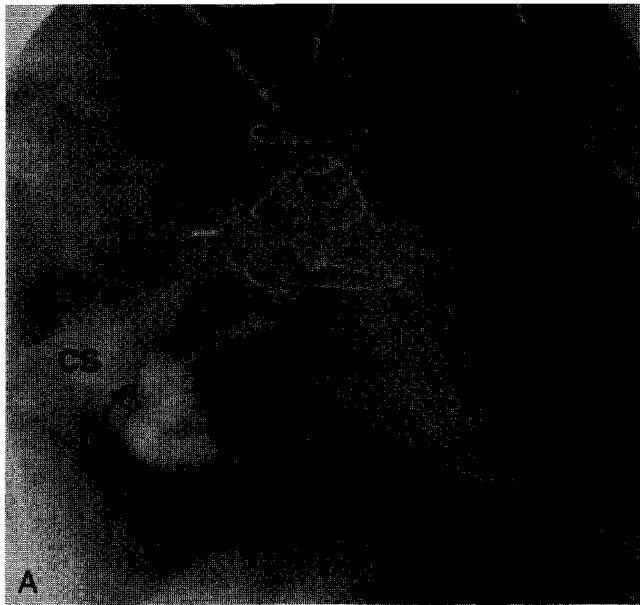


Figure CR4.46. **A.** Angiogram of the RCA, in the right anterior oblique projection, showing a patent posterior descending branch (PD), as well as a membrane-like stenosis (arrow) that partially obstructs the fistula's ostium in the coronary sinus (CS). **B.** Angiogram of the LCA, in the right anterior oblique projection, showing the posterolateral (PL) branch of the RCA, which fills from collaterals that connect with the circumflex artery.

CASE REPORT 4.47**Acquired LCA to Pulmonary Artery Fistula**

A 67-year-old man underwent coronary artery bypass surgery, with placement of a left internal mammary artery graft to the LAD. Eight years postoperatively, follow-up angiography showed that the graft was patent, but abnormal neovasculariza-

tion was noticed (Fig. CR4.47, A–C). The neovessels originated from a diagonal branch and fed a fistula to a left pulmonary arterial branch. The lesion was considered unimportant clinically, and medical treatment was recommended. ■

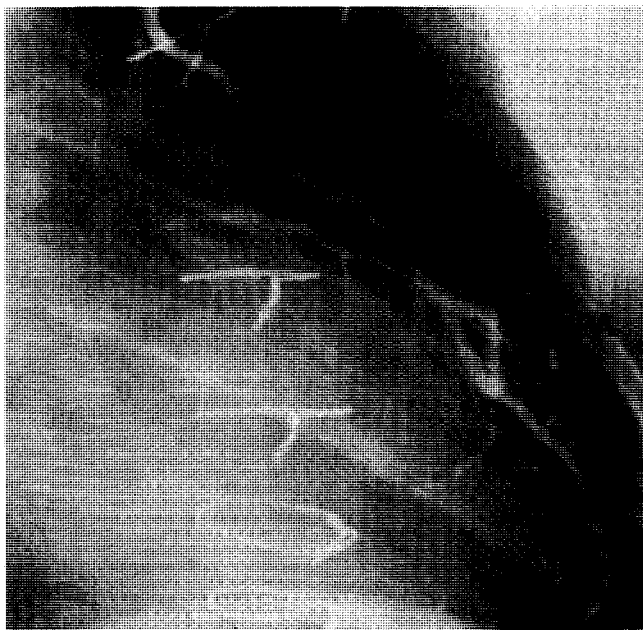
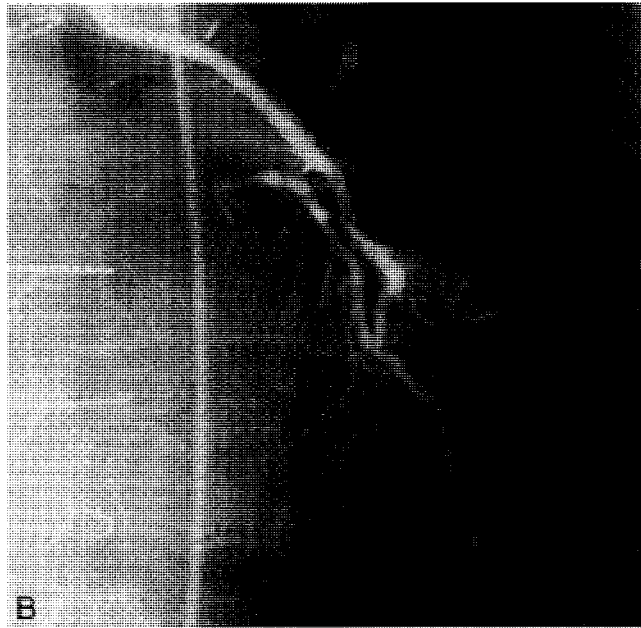
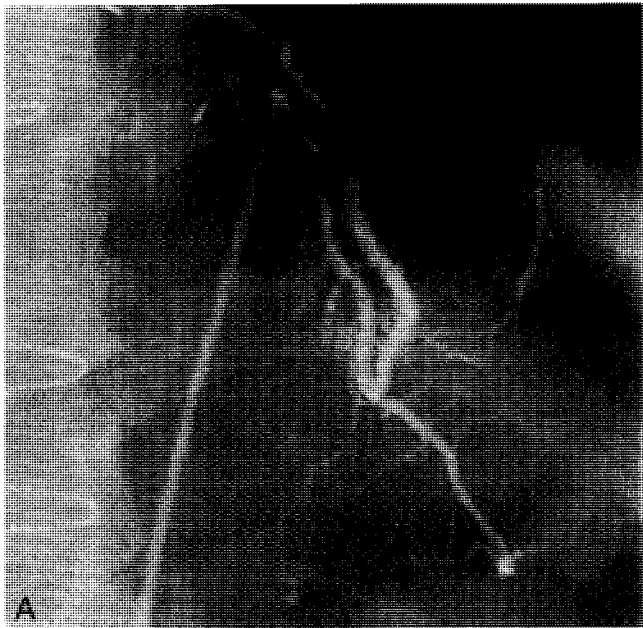

Figure CR4.47. Angiograms of the left internal mammary artery graft in the right anterior (A), posteroanterior (B), and left anterior oblique (C) projections. Abnormal neovessels (not present before coronary artery bypass surgery) fed a left pulmonary artery branch (PA).

CASE REPORT 4.48

LCA to Pulmonary Artery Fistula

A 61-year-old man with exertional chest pain underwent coronary angiography, which failed to reveal coronary artery disease but

showed a small, short coronary to pulmonary artery fistula (Fig. CR4.48, A and B). Medical treatment was recommended. ■

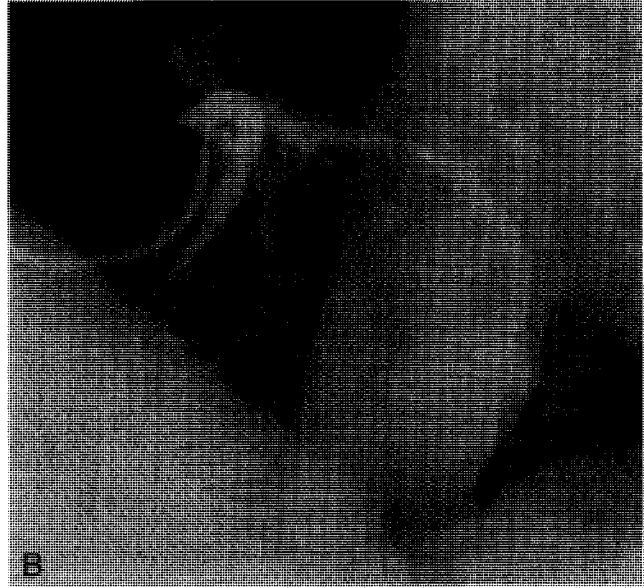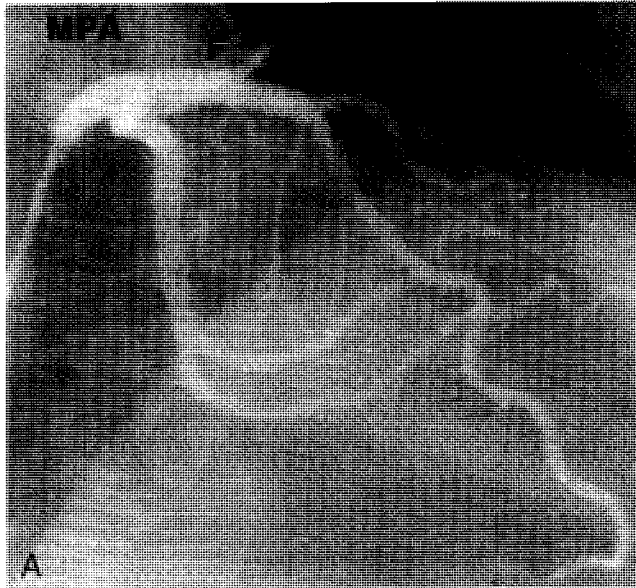


Figure CR4.48. Angiograms of the LCA in the right (A) and left (B) anterior oblique projections. A small fistula (F) arises from the proximal LAD artery and shows faint evidence of filling the main pulmonary artery (view A, MPA).

CASE REPORT 4.49**LCA to Left Ventricular Fistulas**

A 57-year-old man with a history of hypertension and increasingly frequent episodes of angina underwent selective coronary angiography, which failed to indicate fixed coronary obstructive disease. All the coronary main branches were connected to the

left ventricle by means of extensive microfistulas. A nuclear stress test yielded negative results. Medical treatment was continued. ■

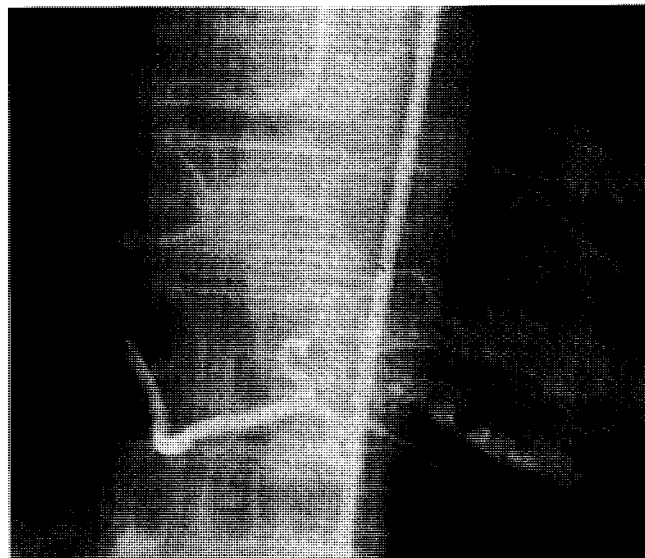
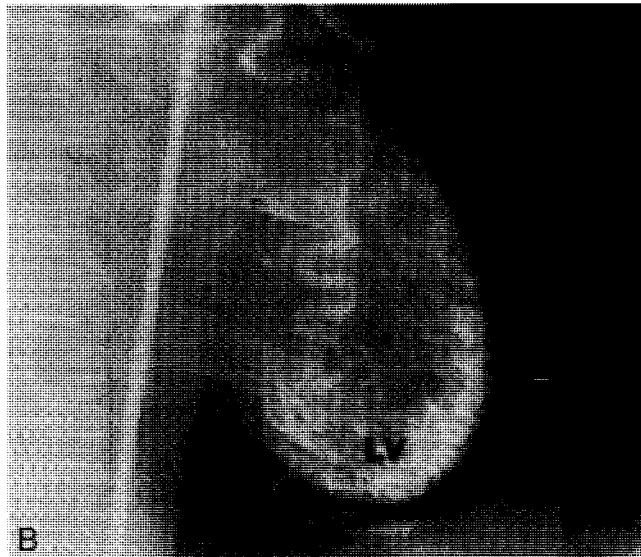
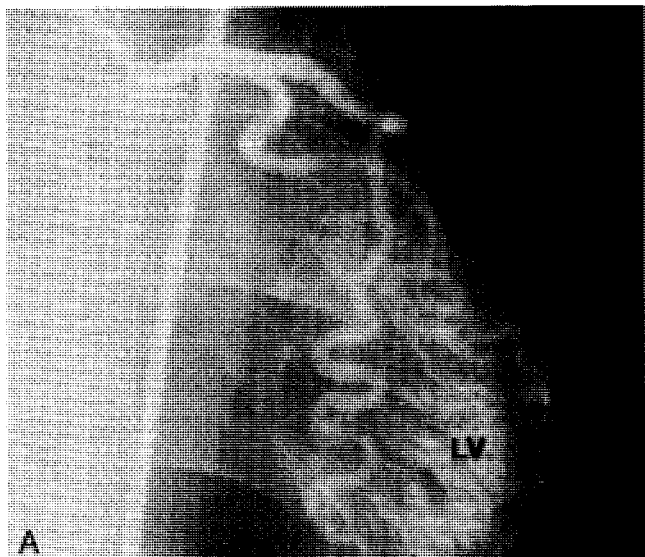Figure CR4.49. Early (A) and late (B) angiograms of the LCA in the right anterior oblique projection, showing the diffuse, "systematic" nature of the patient's multiple small fistulas. In view B, which was obtained at end-diastole, a full ventriculogram becomes apparent. LV = left ventricle. C. Right coronary angiogram, in the posteroanterior projection, showing that the left (but not the right) ventricular branches of the RCA also had microfistulas (F).

CASE REPORT 4.50

Spasm and Coronary Anomalies: A Case of Prinzmetal's Angina and an LAD Muscular Bridge

A 53-year-old man with no history of constitutional risk factors presented with recent-onset chest and jaw pain that occurred at rest and occasionally during exercise; he had been able to continue with a regular exercise program (brisk walking/jogging for 1 hour a day). Nevertheless, treadmill testing was interrupted at 5 minutes because of chest/jaw pain and sudden ST-segment elevation (Fig. CR4.50, A and B) followed by nonsustained polymorphic ventricular tachycardia. The symptoms resolved soon after the administration of sublingual nitroglycerin. Although the patient was treated with a calcium antagonist and a topical nitroglycerin patch, follow-up Holter monitoring continued to show periods of asymptomatic and mildly symptomatic ST-segment changes. Echocardiography showed normal left ventricular function and morphology. Heart catheterization was carried out during pharmacologic withdrawal. Selective coronary angiography (Fig. CR4.50, C and D) revealed a 20% lesion in the RCA and a strictly systolic phasic narrowing (muscular bridge) of the mid LAD. Intravenous ergonovine (0.05 mg) quickly caused reproduction of the patient's symptoms, including electrocardiographic changes (inferior ST-segment elevation and ventricular tachycardia), hypotension, and profuse perspiration. Left coronary angiography revealed an intense fixed LAD stenosis proximal to the area of phasic systolic narrowing (Fig. CR4.50, E and F). Intracoronary nitroglycerin (200 μ g) quickly resolved the symptoms, as well as the electrocardiographic changes and LAD

fixed stenosis (Fig. CR4.50, A–C). Intravascular ultrasound examination of the LAD revealed a systolic concentric narrowing (muscular bridge) of the mid LAD (Fig. CR4.50, G–I) and spasm of the proximal LAD (Fig. CR4.50, J–N). The patient refused to undergo redo ergonovine testing to visualize the RCA, which was the most likely culprit for the ST-segment elevation (inferior leads). He was treated with increased amounts of calcium antagonists and nitrates, which resulted in adequate clinical suppression of the syndrome of Prinzmetal's angina.

This case clearly illustrates the relationship between a congenital coronary anomaly (muscular bridge of the LAD) and a possible mechanism with clinical consequences: coronary spasm. Although the patient indeed had coronary spasm, it was elicited by the ergonovine test not at the site of the LAD muscular bridge but rather at a proximal site, as demonstrated angiographically and by intravascular ultrasound (passage of the device may cause mechanical stimulation at the proximal systolic bend). A site remote from the muscular bridge (the RCA) was actually the culprit for most of the patient's symptoms. More studies are needed to rule out direct involvement of the muscular bridge in Prinzmetal's angina. Interestingly, the site of the LAD spasm in this patient is the site reported in the literature as commonly featuring a fixed stenosis (atherosclerotic proximal LAD muscular bridge). ►

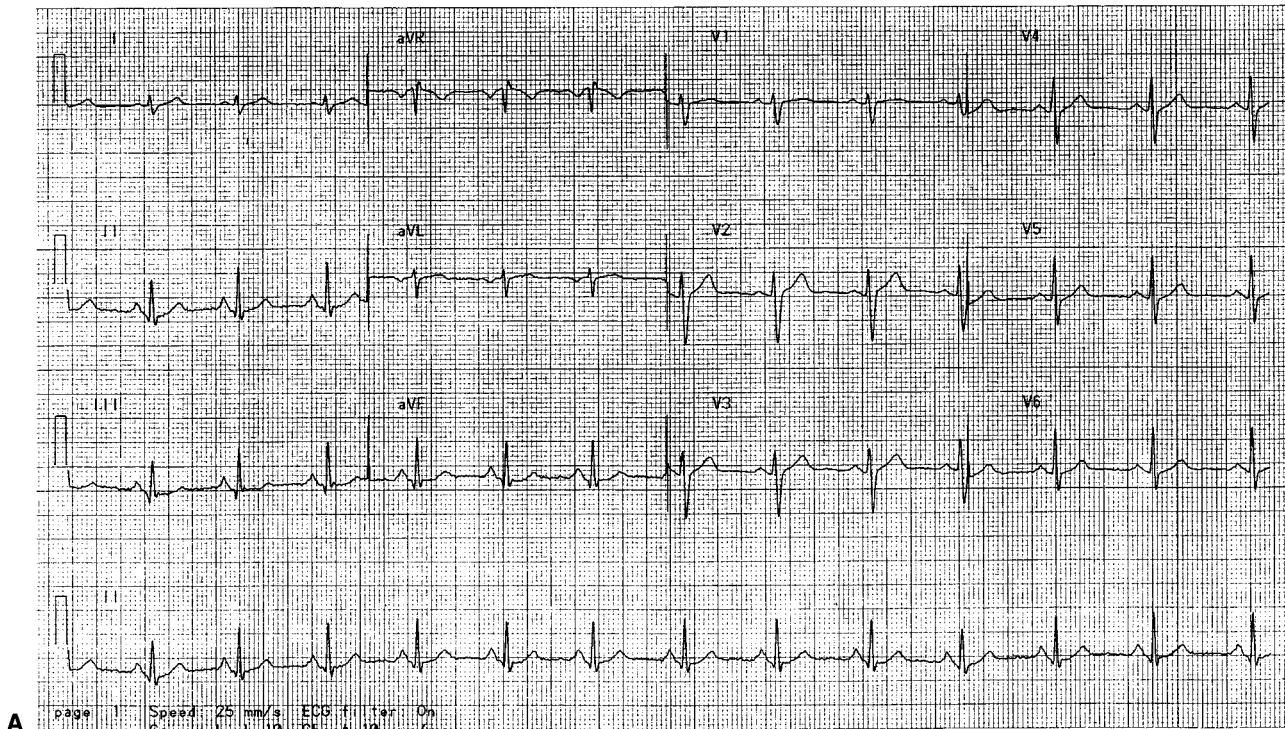


Figure CR4.50. (A) Electrocardiogram at rest (systolic frame). (continued)

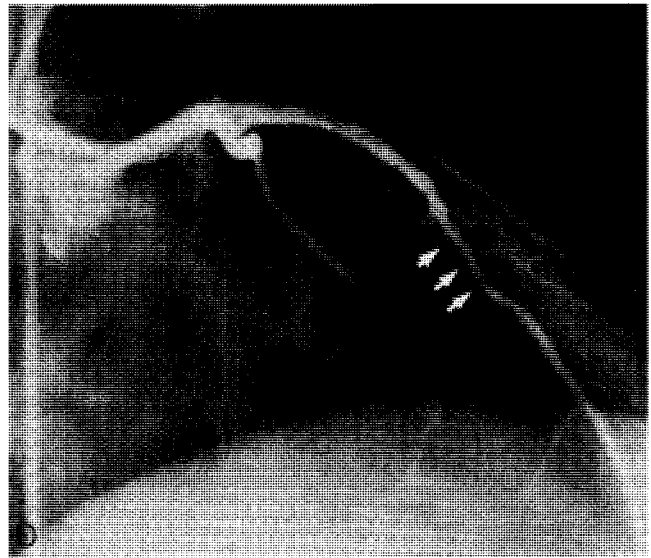
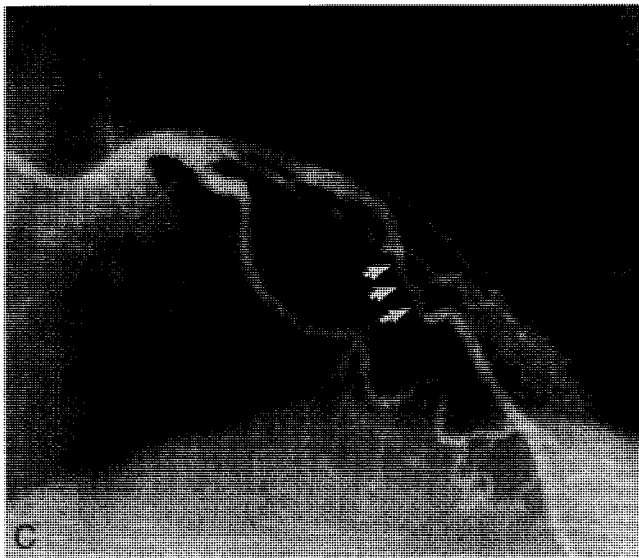
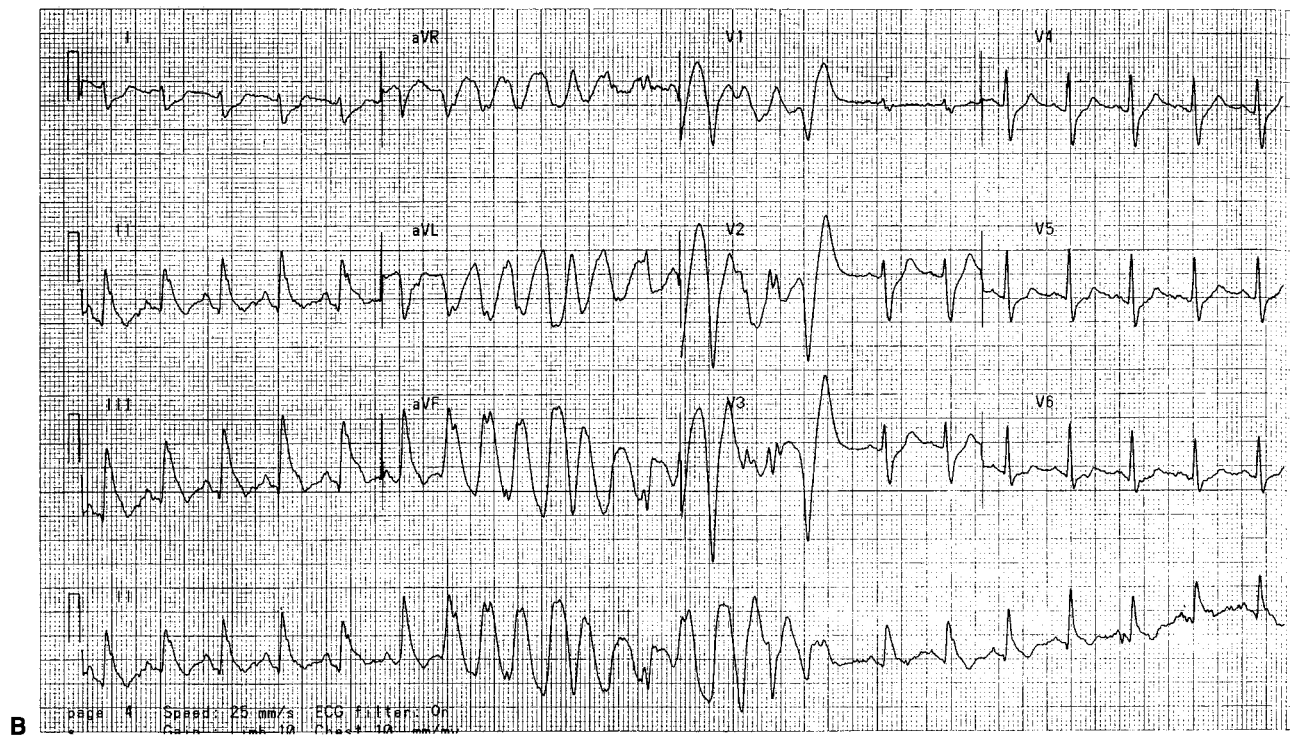


Figure CR4.50. (Continued) **(B)** Electrocardiogram at the end of treadmill exercise (diastolic frame), when ST-segment elevation in the inferior leads was severe and an episode of nonsustained polymorphic ventricular tachycardia was recorded. **C** and **D**. Initial angiograms of the LCA in the right anterior oblique projection during pharmacologic withdrawal. The muscular bridge is indicated by arrows. (continued)

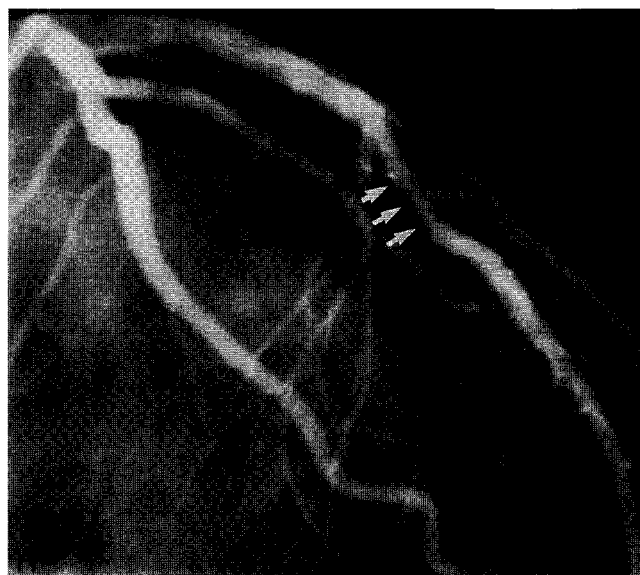
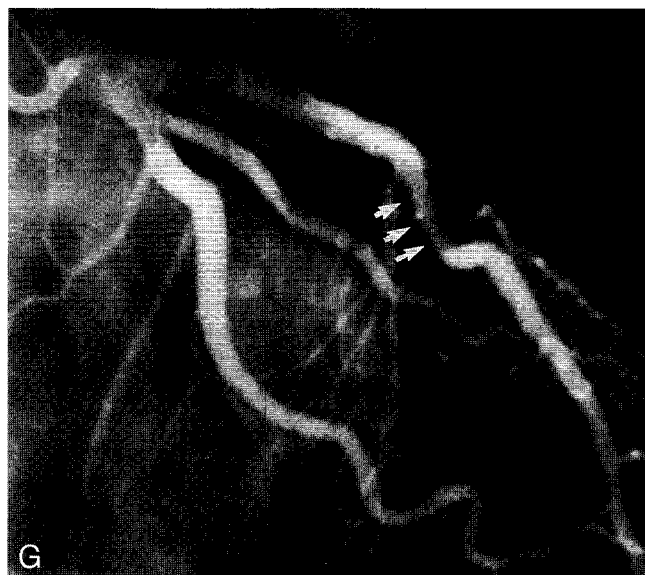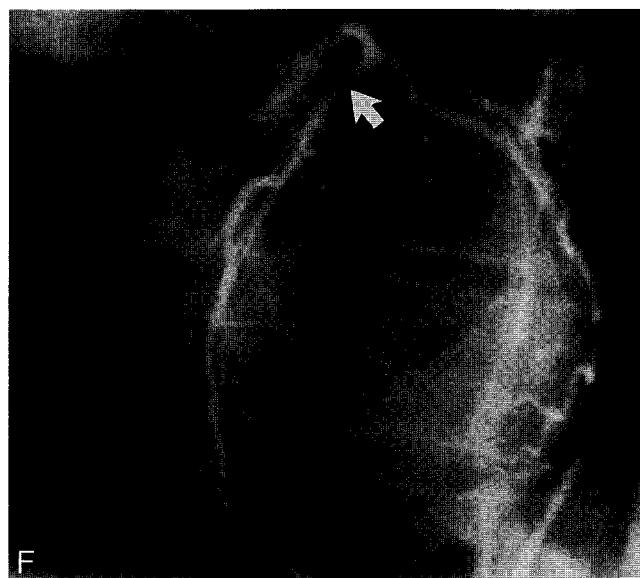
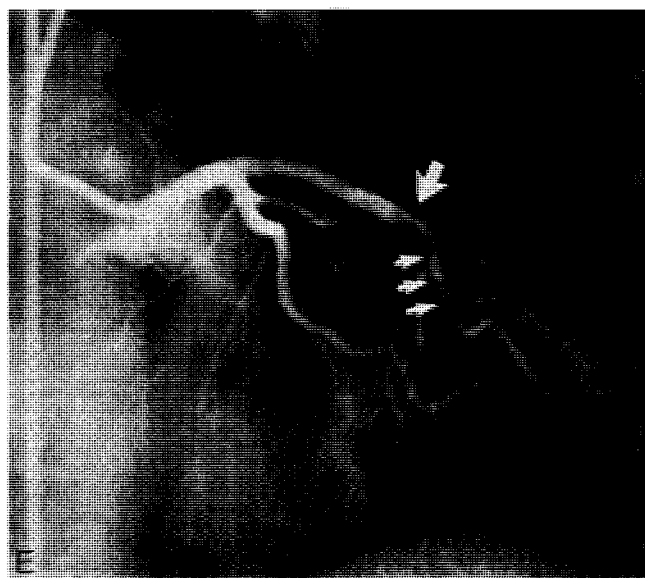


Figure CR4.50. (Continued) **E** and **F.** Angiograms of the LCA obtained 3 minutes after ergonovine administration. **E.** Systolic frame in the right anterior oblique projection. **F.** Diastolic frame in the left anterior oblique projection. Spasm is indicated by the large arrow; muscular bridge-related systolic narrowing is indicated by small arrows. **G–H.** Systolic and diastolic angiographic frames of the LCA in the right anterior oblique projection, showing total resolution of spasm and the persistence of systolic narrowing at the muscular bridge. (continued)

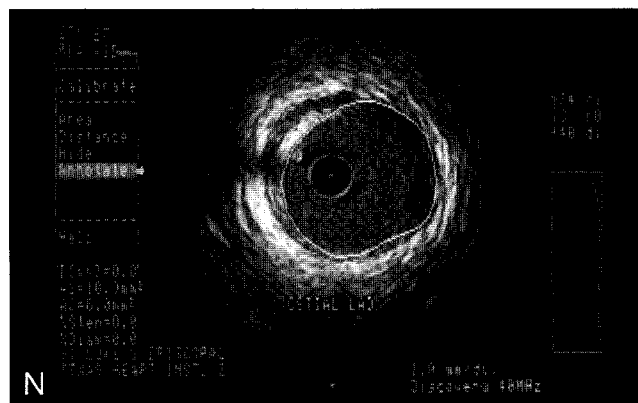
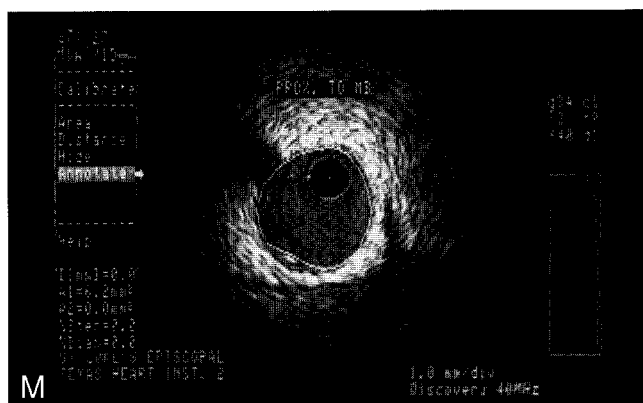
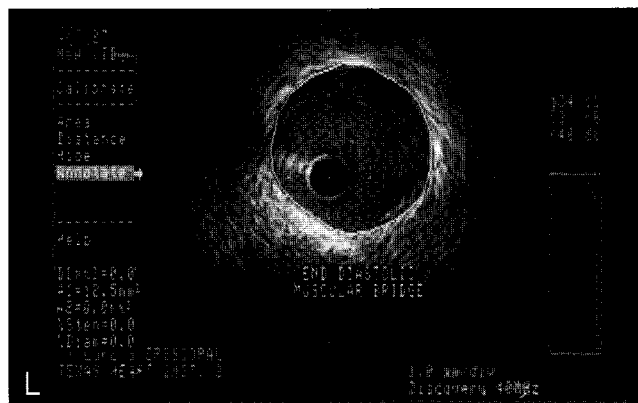
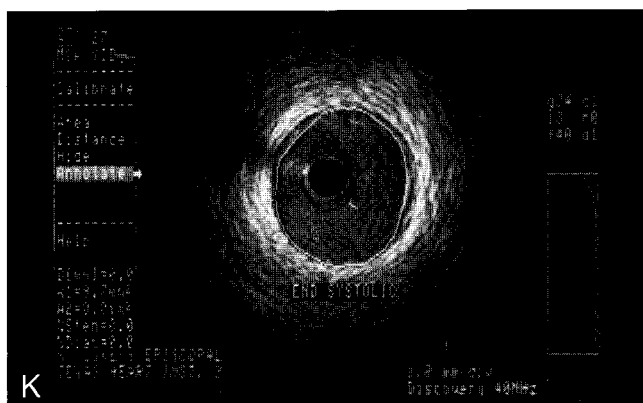
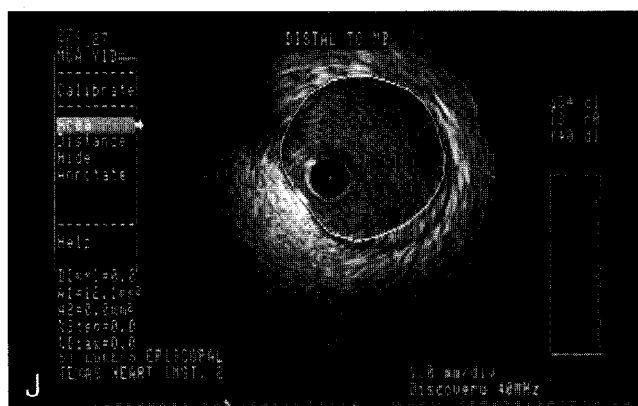
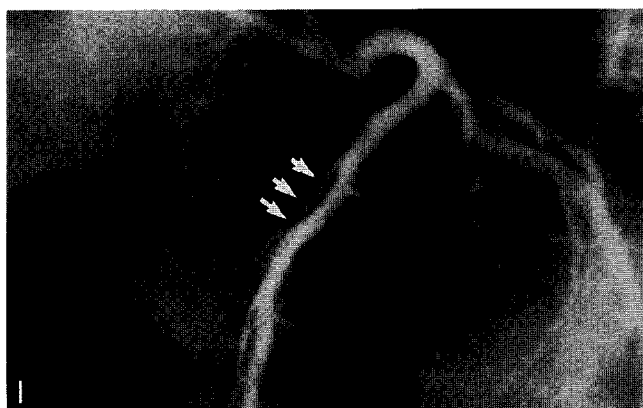

Figure CR4.50. (Continued) I. Diastolic angiographic frame in the left anterior oblique projection, showing total resolution of spasm and the persistence of systolic narrowing at the muscular bridge. J–N. Intracoronary ultrasound images of the LAD, after intracoronary nitroglycerin administration, at the following sites: distal to the muscular bridge (J); at the muscular bridge (end-systole) (K); at the muscular bridge (end-diastole) (L); at the bend, proximal to the muscular bridge (M); and at the LAD ostium (just distal to the circumflex separation) (N). Note that passage of the ultrasound catheter caused spasm at the proximal LAD bend (view M), most likely because of mechanical stimulation. Area calculations are indicated in each view.